



## EVIDENCE SUMMARY

### Among individuals suspected of COVID-19, how accurate are thoracic imaging modalities compared to RT-PCR alone in diagnosing COVID-19?

Update by: Giselle Anne Q. Adajar, MD; Michelle Cristine B. Miranda, MD; Howell Henrian Bayona, MSc

Initial review by:

- Chest X-ray: Maria Cristina Z. San Jose, MD and Valentin C. Dones, PTRP, MSPT, PhD
- Lung Ultrasound: Aldrich Ivan Lois Burog, MD, Ian Theodore Cabaluna, MD
- Chest CT scan: Myzelle Anne J. Infantado, PTRP, MSc (cand.), Cary Amiel G. Villanueva, MD

## RECOMMENDATIONS

### Chest X-Ray

**We suggest against the use of chest x-ray to diagnose COVID-19 infection among asymptomatic individuals.** (*Very low certainty of evidence; Weak recommendation*)

**We suggest chest x-ray to facilitate rapid triage, infection control, and clinical management among any of the following:** (*Very low certainty of evidence; Weak recommendation*)

- patients with mild features of COVID-19 at risk for progression
- patients with moderate to severe features of COVID 19
- patients with symptoms of at least 5 days duration

### Lung Ultrasound

**We suggest against the use of lung ultrasound alone in diagnosing patients with suspected COVID-19 infection.** (*Very low certainty of evidence; Weak recommendation*)

### Chest CT Scan

**We suggest against the routine use of CT scan for diagnosing COVID-19 among suspected patients with COVID-19 presenting at the emergency department if RT-PCR testing is readily available with timely results.** (*Very low certainty of evidence; Weak recommendation*)

**If RT-PCR is not available, we suggest using non-contrast chest CT scan for symptomatic patients suspected of having COVID-19 to guide early triage and management under the following conditions:** (*Very low certainty of evidence; Weak recommendation*)

- Mild COVID-19 patients who are at risk for progression
- Moderate to severe COVID-19 patients



# Philippine COVID-19 Living Clinical Practice Guidelines

## *Consensus Issues*

The panel was unanimous against the use of chest x-ray and lung ultrasound in diagnosing COVID-19 due to the widespread availability of alternatives, such as antigen testing, even in the absence of RT-PCR. Additionally, the evidence base showed that detecting COVID-19 through these imaging modalities are dependent on the experience of the reader. However, a weak recommendation was decided since the evidence did not compare these imaging modalities with rapid antigen tests.

The panel was also unanimous in recommending chest x-ray to facilitate triage, infection control, and clinical management, especially in the absence of RT-PCR and rapid antigen tests, due to the widespread availability and rapid results of chest x-ray. A weak recommendation was made, however, since the accuracy of this modality varies depending on the experience of the reader.

Similarly, the panel was for the use of non-contrast chest CT scan in guiding early triage and clinical management if RT-PCR is not available. A weak recommendation for this was made due to concerns on its risk of radiation and cost, and the evidence base including studies conducted abroad.

## **PREVIOUS RECOMMENDATION**

### **Chest X-Ray**

We suggest against the use of chest x-ray to diagnose COVID-19 infection among asymptomatic individuals (*Very low quality of evidence; Conditional recommendation*).

We suggest chest x-ray to facilitate rapid triage, infection control and clinical management among any of the following (*Very low quality of evidence; Conditional recommendation*):

- patients with mild features of COVID 19 at risk for progression
- patients with moderate to severe features of COVID 19
- patients with symptoms of at least 5 days duration

### *Consensus Issues*

The use of chest X-ray to diagnose COVID-19 infection among asymptomatic individuals was not suggested due to the very low quality of evidence related to its diagnostic accuracy. High heterogeneity across studies was also observed and the studies reviewed did not perform subgroup analysis according to severity of COVID-19. However, chest x-ray is still suggested for specific instances as there would be a high yield in detecting significant pulmonary abnormalities in these settings.

### **Lung Ultrasound**

We suggest against the use of lung ultrasound alone in diagnosing patients with suspected COVID-19 infection. (*Low quality of evidence, Conditional recommendation*)

### *Consensus Issues*

Majority of the panelists voted for a conditional recommendation against lung ultrasound alone due to the low quality of evidence related to its diagnostic accuracy. Some panelists argued that a strong recommendation against the use of lung ultrasound alone in diagnosing suspected COVID-19 patients should be made since it has not been found to be as accurate



## Philippine COVID-19 Living Clinical Practice Guidelines

as the current gold standard, which is RT-PCR. Despite its limitations, lung ultrasound is still considered a valuable prognostic tool to assess clinical deterioration as it can predict the presence of abnormalities in the lung findings of COVID-19 patients.

### **Chest CT Scan**

We suggest against the routine use of CT scan for diagnosing COVID-19 among suspected patients with COVID-19 presenting at the emergency department if RT-PCR testing is readily available with timely results. (*Very low quality of evidence; Conditional recommendation*).

If RT-PCR test is not available, we suggest using non-contrast chest CT scan for symptomatic patients suspected of having COVID-19 to guide early triage and management under the following conditions (*Very low quality of evidence; Conditional recommendation*):

- Mild COVID-19 patients who are at risk for progression
- Moderate to severe COVID-19 patients

### What's new in this version?

- This review update combined evidence from three previous reviews on chest x-ray, lung ultrasound, and chest CT-scan.
- There are seven new observational studies for chest x-ray, three new observational studies for the lung ultrasound and 20 new observational studies for chest CT scan.
- Additional subgroup analysis was done, particularly on the presence of symptoms, timing of testing, reader experience and on the category of index test positivity.
- Previous recommendations were retained except for the downgrading of the certainty of evidence for lung ultrasound from “Low” to “Very Low”.

### Key Findings

- A total of 81 observational studies were assessed for the diagnostic accuracy of chest x-ray, lung ultrasound, and chest CT scan against reverse transcriptase-polymerase chain reaction (RT-PCR) on individuals suspected of COVID-19.
- **Chest x-ray:** Overall sensitivity was 72% (62-81%) and overall specificity was 76% (67-86%). Results were comparable to the findings of the previous review that showed a sensitivity of 74% and specificity of 76%. Considerable heterogeneity is still seen ( $I^2=95%$ ). Sensitivity was higher for studies that involved experienced readers, used standardized chest x-ray scoring systems, and when testing was done late in the disease course. Studies with high risk of bias tended to produce similar but less precise estimates. Overall certainty of evidence remained very low due to very serious risk of bias and inconsistency, and serious imprecision.
- **Lung ultrasound:** Overall sensitivity was 93% (86-97%) and specificity was 52% (33-71%). The previous review showed a lower sensitivity of 88% but a higher specificity of 63%. Sensitivity appeared higher when the test is used for symptomatic patients and when reader impression is used instead of a scoring system. The highest accuracy estimates were produced when only high quality studies were included in the analysis (Sn 97%, 95% CI 89, 100%; Sp 73%, 95% CI 45, 92%). Overall certainty of evidence was downgraded from low to very low due to very serious inconsistency, and seriousness on risk of bias and imprecision.
- **Chest CT scan:** Overall sensitivity was 85% (81-88%) and overall specificity was 78% (71-84%). Heterogeneity was very high at  $I^2=100%$ . Findings were almost similar to the estimates (Sn 88% and Sp 80%) of the previous review. Accuracy estimates were higher under the following situations: (1) test is used among symptomatic patients, (2) contrast-



# Philippine COVID-19 Living Clinical Practice Guidelines

enhanced CT scan machines, (3) results are interpreted by experienced readers, (4) standardized scoring systems are used, (5) when only high-quality studies were considered. Overall certainty of evidence remained very low due to the seriousness of risk of bias and impression, and the very serious issues on inconsistency.

## Introduction

Timely and appropriate assessment is necessary for patients who are suspected to have COVID-19. The current reference standard for the diagnosis of COVID-19 is the reverse transcriptase polymerase chain reaction (RT-PCR). This requires sophisticated equipment and trained specialists, and may take at least 24 hours to produce results.[1] In settings where RT-PCR is not available, chest imaging plays an important role in the diagnostic work-up of suspected symptomatic COVID-19 individuals.[2]

Present literature on COVID-19 is dominated by chest computed tomography (CT) scan as a primary imaging modality.[3,4] Some hospitals have set up CT scan machines dedicated solely for suspected COVID-19 patients. However, this may not be accessible, affordable, and feasible in primary care settings. In contrast, chest x-ray is more ubiquitous, readily available, and produces less radiation compared to CT scan.[5] Lung ultrasound is likewise accessible and can be used at the bedside but is limited by its inability to provide a comprehensive view of deep portions of lung parenchyma.[6,7] The accuracy of these diagnostic modalities may vary depending on the level of experience of the radiologist or reader.[8]

This review update collated previous evidence summaries related to the diagnostic accuracy of these thoracic imaging modalities compared to RT-PCR alone in diagnosing COVID-19 among individuals suspected of COVID-19.

## Review Methods

### Search Strategy

A literature search for studies published from January 2020 to November 20, 2021 on the following electronic databases was conducted: MEDLINE, COVID-19 Living Evidence Database ([https://zika.ispm.unibe.ch/assets/data/pub/search\\_beta/](https://zika.ispm.unibe.ch/assets/data/pub/search_beta/)) and Cochrane COVID-19 Study Register ([covid-19.cochrane.org/](https://covid-19.cochrane.org/)) using subject headings combined with text words related to “chest xray,” “chest radiograph,” “chest ultrasound,” “lung ultrasound,” “chest computed tomography scan,” “polymerase chain reaction, reverse transcriptase,” “COVID-19,” “SARS-Cov-2” with no language limits or method filters. To supplement the initial yield, the references sections of the included studies were reviewed for relevant articles.

### Eligibility Criteria

This review included observational studies, randomized controlled trials (RCTs), and systematic reviews of observational studies that evaluated the diagnostic accuracy of the three imaging modalities for diagnosing COVID-19 among individuals suspected of COVID-19. Index tests included chest radiograph, lung ultrasound, and chest CT scan. Reference standard was a positive RT-PCR test for SARS-CoV-2 infection. Articles that had no available full text reports or did not have sufficient data to produce estimates of test accuracy or provide data for a 2x2 contingency table were excluded. Case reports and case series were also excluded. Studies that involved only PCR-positive samples were excluded as well. Appendix 3 lists the included studies.

### Data Analysis

The studies were appraised using the QUADAS-2 tool. Measures of diagnostic accuracy, such as sensitivity and specificity values, were pooled using STATA version 14 and MetaDTA v2.01



# Philippine COVID-19 Living Clinical Practice Guidelines

([https://crsu.shinyapps.io/dta\\_ma/](https://crsu.shinyapps.io/dta_ma/)). Heterogeneity was determined by calculating  $I^2$  using STATA version 14 and visual inspection of the forest plot. Subgroup analysis on symptomatology, timing of testing in relation to onset of symptoms, and category of index test positivity were performed depending on data availability. Sensitivity analyses were performed to determine the impact of risk of bias on sensitivity or specificity estimates.

## Results

The initial search yielded a total of 1,032 titles and abstracts. With the application of the criteria and the removal of articles with duplicates and articles with incomplete data, a total 81 observational studies (11 on chest x-ray alone, four on lung ultrasound alone, 56 on chest CT alone, three on both chest x-ray and chest CT scan, four on both lung ultrasound and chest x-ray, and three on both lung ultrasound and chest CT scan) were included in this evidence summary.

### Chest X-Ray

#### **A. Characteristics of Included Studies**

The diagnostic accuracy of chest x-ray was reported in 18 observational studies (ten retrospective cohort, six prospective cohort, and two case-control studies) involving various countries with a mix of adult and pediatric patient populations (n=9,616).[9-26] Seven new studies were added from the previous review. COVID-19 was confirmed using RT-PCR in these populations. Of these 18 studies, 13 (72%) involved symptomatic patients, one (6%) involved asymptomatic patients, and four (22%) recruited patients with mixed symptom profiles. There were no studies with specific data on the severity of COVID-19 on presentation, the vaccination status of patients, or the predominant COVID-19 variant that was prevalent during the time of the study.

Eleven studies (61%) did not specify the type of machine used, while seven of 18 (39%) studies used portable or bedside x-rays. Experienced radiologists or readers were involved in eleven studies (61%), while two studies (11%) involved inexperienced readers. The rest of the studies did not specify the reader experience. In the included studies, inexperienced readers were non-radiologist readers or radiologists with less than five years of experience.

Definitions of positive chest x-ray results varied considerably across studies but most studies used common findings seen in radiographs of patients with COVID-19 pneumonia (e.g., presence of ground-glass/peripheral/interstitial/alveolar opacities, consolidations, reticulations, pleural effusion, atelectasis, among others). Most studies used the overall impression of readers as the basis for a positive result, eight studies used previously established scoring systems (i.e. The British Society of Thoracic Imaging or BTSI reporting criteria; Radiographic Assessment of Lung Edema or RALE criteria), and three studies used unvalidated classification systems involving Likert scales.

The detailed characteristics of included studies are described in Appendix 3.

#### **B. Overall certainty of evidence**

The overall certainty of evidence for the diagnostic accuracy of chest x-ray was very low. Very serious risk of bias was noted in the studies (10 studies with high risk of bias and eight with unclear risk of bias). There were very serious issues on inconsistency due to considerable heterogeneity, and serious issues of imprecision due to wide confidence interval values (See Appendix 4 for the Risk of Bias Ratings and Appendix 6 for the GRADE Evidence Profile).



## C. Outcomes

### *Diagnostic performance of chest x-ray*

Chest x-ray showed a pooled sensitivity of 72% (95% CI 0.62, 0.81) and specificity of 78% (95% CI 0.67, 0.86) in diagnosing COVID-19. Significant heterogeneity was observed across studies ( $I^2=95%$ ) possibly due to several factors: presence of symptoms, experience of chest x-ray readers, timing of chest x-ray in relation to symptom onset, definition of index test positivity. The previous review showed a sensitivity of 74% (95% CI 0.59, 0.85) and specificity of 76% (95% CI 0.67, 0.83).[5] (See Appendix 5 for the Forest Plot)

Results of the subgroup analyses are summarized in Table 1. Subgroup analysis based on population characteristics (age and severity of disease) was not possible due to the lack of available aggregated data.

Table 1. Subgroup analyses of the diagnostic accuracy of chest x-ray for detecting COVID-19 infection

Subgroups	No. of Studies	n	Sensitivity	95% CI	Specificity	95% CI
<b>Presence of Symptoms</b>						
Symptomatic	13	4,164	0.74	0.64, 0.83	0.76	0.67, 0.83
Asymptomatic	1	85	0.75	0.19, 0.99	0.74	0.63, 0.83
Mixed	4	1,899	0.79	0.66, 0.87	0.58	0.47, 0.68
<b>Reader Experience</b>						
Experienced	11	4,531	0.64	0.50, 0.76	0.87	0.74, 0.94
Inexperienced	2	572	0.24	0.12, 0.43	0.99	0.80, 0.99
<b>Timing of Testing in Relation to Symptom Onset</b>						
Early	3	810	0.37-0.55	-	0.65-0.83	-
Late	3	572	0.75-0.79	-	0.49-0.79	-
Mixed	7	2,195	0.72	0.58, 0.82	0.74	0.63, 0.82
<b>Category of Index Test Positivity</b>						
Reader impression	10	6,586	0.65	0.49, 0.77	0.82	0.67, 0.91
Scoring system	8	3,041	0.81	0.69, 0.88	0.71	0.59, 0.81
<b>Sensitivity Analysis</b>						
High risk of bias	10	5,944	0.69	0.52, 0.83	0.81	0.64, 0.91

### 1. Presence of Symptoms

Although the pooled sensitivity and specificity of chest x-ray appeared comparable between symptomatic (Sn 0.74; Sp 0.76) and asymptomatic patients (Sn 0.75; Sp 0.74), data on asymptomatic patients were reported in only one study, and with imprecise results.[15]

### 2. Reader Experience

Studies involving experienced radiologists reported significantly higher sensitivity (Sn 0.64) than less or inexperienced readers (Sn 0.24). The level of experience did not appear to significantly influence the test specificity (Sp 0.87 in experienced vs. Sp 0.99 in less or inexperienced readers).

### 3. Timing of Testing in Relation to Symptom Onset

Only three studies had specific data on the timing of chest x-ray in relation to symptom onset.[15,17,24] These studies had varying cut-offs for early and late timing of testing. In one study, early testing was defined as three days or less from the symptom onset.[15] The other study used five days as the cut-off.[17] The third study was able to compute the diagnostic accuracy of chest x-ray performed within two days from symptom onset and within 11 days after symptom onset.[24] Pooling of the estimates was not done due to the varying definitions. Range Sensitivity of chest x-ray increased over time (Early Sn 0.37-0.55 vs. Late Sn 0.75-0.79) while the specificity of chest x-ray decreased (Early Sp 0.65-0.83 vs. Late Sp 0.49-0.70) over time.



## Philippine COVID-19 Living Clinical Practice Guidelines

### 4. Index Test Positivity

Using a scoring system in evaluating chest x-ray offers an advantage (Sn 0.81, 95% CI 0.69, 0.88) compared to a reader's impression (Sn 0.65, 95% CI 0.49, 0.77).

### 5. Sensitivity Analysis

Studies with high risk of bias showed a negative effect on the sensitivity of chest x-ray (Sn 0.69, 95% CI 0.52, 0.83). Studies with unclear risk of bias showed comparable sensitivity (Sn 0.74, 95% CI 0.64, 0.82) and specificity (Sp 0.72, 95% CI 0.56, 0.84) with the overall estimates.

### Common findings and distribution on initial chest x-ray

Among the included studies, six had data on the common chest x-ray findings.[17-19,22,24,26] Table 2 summarizes the abnormalities found on chest x-rays in individuals with COVID-19. The most common findings included the presence of opacities (four studies, 1.4-86.1%) specifically ground glass opacities (two studies, 26.1-30.5%), followed by reticular opacities (one study, 29.7%), and alveolar opacities (one study, 25.9%). The presence of consolidations (three studies, 1.4%-66.8%) and pleural effusion (four studies, 2.6-6.4%) were likewise reported. In chest x-ray findings, lesions were most likely to present with alveolar pattern (one study, 86.1%), with bilateral lung involvement (five studies, 23.9-85%), multiple lung lobe involvement (two studies, 4.5-25.3%), and lower lobe involvement (one study, 83.7%).

One study noted that alveolar and reticular opacities were common findings seen in chest x-rays performed within five days from symptom onset.[17] Same features were found in chest x-rays performed after five days from symptom onset. More samples with bilateral and multilobular involvement were found in chest x-rays performed after five days from symptom onset compared to those done earlier.

Table 2. Common findings on chest x-ray

Chest x-ray findings	No. of studies	Prevalence in studies	No. of reported cases	Total no. of patients	Percentage of patients
<b>FEATURES</b>					
<b>Presence of opacities</b>	<b>4</b>	<b>1.4-86.1%</b>	<b>1,524</b>	<b>6,644</b>	<b>22.9%</b>
Ground glass opacities	2	26.1-30.5%	55	193	28.5%
Peripheral opacities	1	10.4%	52	500	10.4%
Interstitial and airspace opacities	1	25.4%	127	500	25.4%
Diffuse airspace opacities	1	3.0%	15	500	3.0%
Alveolar opacities	1	25.9%	134	518	25.9%
Reticular opacities	1	29.7%	154	518	29.7%
<b>Consolidation</b>	<b>3</b>	<b>1.4-66.8%</b>	<b>407</b>	<b>1,138</b>	<b>35.8%</b>
<b>Pleural effusion</b>	<b>4</b>	<b>2.6-6.4%</b>	<b>64</b>	<b>1,656</b>	<b>3.9%</b>



## Philippine COVID-19 Living Clinical Practice Guidelines

Chest x-ray findings	No. of studies	Prevalence in studies	No. of reported cases	Total no. of patients	Percentage of patients
<b>DISTRIBUTION OF LESIONS</b>					
<b>Pattern of lesion</b>					
Interstitial	1	42.0%	37	88	42.0%
Alveolar	1	86.1%	459	533	86.1%
<b>Laterality of lesion</b>					
Bilateral	5	23.9-85%	702	1,373	51.1%
Unilateral	2	4.7-7.6%	14	234	6.0%
<b>Lobar involvement</b>					
Unilobular	1	8.0%	7	88	8.0%
Multilobular	2	4.5-25.3%	135	606	22.3%
<b>Lobar location</b>					
Upper lobe	1	0.2%	1	533	0.2%
Lower lobe	1	83.7%	446	533	83.7%
Upper and lower lobe	1	3.2%	17	533	3.2%
<b>FEATURES FOUND IN CHEST X-RAY DONE WITHIN 5 DAYS FROM SYMPTOM ONSET</b>					
<b>Lesions</b>					
Alveolar opacities	1	17.2%	46	372	12.4%
Reticular opacities	1	17.2%	64	372	17.2%
Pleural effusion	1	4.8%	18	372	4.8%
<b>DISTRIBUTION OF LESIONS IN CHEST X-RAY DONE WITHIN 5 DAYS FROM SYMPTOM ONSET</b>					
<b>Laterality of lesion</b>					
Bilateral	1	11.8%	44	372	11.8%
<b>Lobar involvement</b>					
Multilobular	1	12.9%	48	372	12.9%
<b>FEATURES FOUND IN CHEST X-RAY DONE AFTER 5 DAYS FROM SYMPTOM ONSET</b>					
<b>Lesions</b>					
Alveolar opacities	1	60.3%	88	146	60.3%
Reticular opacities	1	61.6%	90	146	61.6%
Pleural effusion	1	8.2%	12	146	8.2%
<b>DISTRIBUTION OF LESIONS IN CHEST X-RAY DONE AFTER 5 DAYS FROM SYMPTOM ONSET</b>					
<b>Laterality of lesion</b>					
Bilateral	1	84.9%	124	146	84.9%
<b>Lobar involvement</b>					
Multilobular	1	83.6%	122	146	83.6%

### Lung Ultrasound

#### A. Characteristics of Included Studies

The diagnostic accuracy of lung ultrasound was reported in 11 observational studies (nine prospective cohort studies and two retrospective cohort studies) involving exclusively adult population from multiple countries (n=1,076).[13,21,22,26-33] Three new studies were added from the previous review. All studies used POCUS (Point-of-Care Ultrasound). Nine out of 11 studies were done in the emergency room setting. Ten studies involved symptomatic patients and only one study involved asymptomatic patients. There were no studies with specific data on the vaccination status of patients or the predominant COVID-19 variant that was prevalent during the time of the study. All studies used RT-PCR as the reference standard for the diagnosis of COVID-19.

Experienced readers were involved in most (8/11 or 72%) of the studies, while one study involved inexperienced readers. While most studies relied on reader impression on the ascertainment of a positive diagnosis, two studies used formal scoring systems like the POCUS (Point-of-Care Ultrasound) for pulmonary manifestations of COVID-19. Positive characteristics in lung ultrasound





## Philippine COVID-19 Living Clinical Practice Guidelines

include the presence of B-lines or the presence of vertical hyperechoic artifacts departing from the pleura and directing in-depth, representing thickened peripheral interlobular septa. There were variations in the brand of ultrasound machine, type of probe used (curvilinear, curved, Butterfly IQ), and scanning protocols applied (e.g., BLUE protocol, 12-zone, 8-zone).

### **B. Overall certainty of evidence**

The overall certainty of evidence for the diagnostic accuracy of lung ultrasound was very low. Serious risk of bias was noted in some studies (five with high risk of bias and five with unclear risk of bias). In all four domains of QUADAS-2, unclear risk of bias was mostly seen. Very serious issues on inconsistency was due to considerable heterogeneity. There was seriousness on imprecision due to wide confidence interval values (See Appendix 4 for the Risk of Bias Ratings and Appendix 6 for the GRADE Evidence Profile).

### **C. Outcomes**

#### Diagnostic performance of lung ultrasound

Lung ultrasound demonstrated a pooled sensitivity of 93% (95% CI 0.86, 0.97) and specificity of 52% (95% CI 0.33, 0.71) in diagnosing COVID-19. Similar to chest x-ray, significant heterogeneity was observed across studies ( $I^2=98\%$ ), possibly because of a number of factors, including the number of patients sampled per study, definition of index test positivity, and experience of readers. The previous review showed a sensitivity of 88% (95% CI 0.79, 0.93) and a specificity of 63% (95% CI 0.47, 0.77).[34]

Table 3 shows the subgroup analyses based on presence of symptoms, reader experience, and index test of positivity. Subgroup analyses based on population characteristics (age, severity of disease) and timing of testing were not done due to insufficient aggregated data.

Table 3. Subgroup analyses of the diagnostic accuracy of lung ultrasound for detecting COVID-19 infection

Subgroups	No. of Studies	n	Sensitivity	95% CI	Specificity	95% CI
<b>Presence of Symptoms</b>						
Symptomatic	10	918	0.93	0.85, 0.97	0.50	0.29, 0.72
Asymptomatic	1	58	0.70	0.51, 0.84	0.68	0.46, 0.85
<b>Reader Experience</b>						
Experienced	8	738	0.95	0.88, 0.98	0.43	0.23, 0.67
Inexperienced	1	101	0.97	0.89, 1.0	0.14	0.05, 0.29
<b>Category of Index Test Positivity</b>						
Reader impression	9	833	0.95	0.86, 0.98	0.52	0.28, 0.75
Scoring system	2	243	0.86	0.64, 0.96	0.58	0.49, 0.67
<b>Sensitivity Analysis</b>						
High risk of bias	5	512	0.97	0.89, 0.99	0.37	0.14, 0.67
Unclear risk of bias	5	487	0.83	0.69, 0.92	0.64	0.39, 0.83
Low risk of bias	1	77	0.97	0.89, 1.0	0.73	0.45, 0.92

#### *1. Presence of Symptoms*

Ten studies had specific data on the use of lung ultrasound on symptomatic suspected COVID-19 patients. This yielded a sensitivity of 93% (95% CI 0.85, 0.97). One study showed a lower sensitivity ( $S_n$  0.70, 95% CI 0.51, 0.84) for asymptomatic patients. This study was done in a setting of a nursing home. These asymptomatic patients were contacts of positive COVID-19 patients in the nursing home.[29]



## Philippine COVID-19 Living Clinical Practice Guidelines

### 2. Reader Experience

Inexperienced readers had comparable sensitivity with the experienced reader (Sn 97% vs. Sn 95%). Specificity was much lower (Sn 0.14, 95% CI 0.05, 0.29) with inexperienced readers. However, data on inexperienced readers was limited to a single study and the estimates were less precise. Inexperienced readers in that study were first to third year emergency medicine residents with credentials for point-of-care ultrasound that reviewed a two-minute video on lung ultrasound findings for viral pneumonia prior to the start of study.[13] They have less experience compared to the other readers in the included studies.

### 3. Index Test Positivity

In determining a positive lung ultrasound result, a reader's impression showed a higher sensitivity (Sn 0.95, 95% CI 0.86, 0.98) compared to using a scoring system (Sn 0.86, 95% CI 0.64, 0.96). Specificity between the two were comparable (Sp 0.52 vs. Sp 0.58). Data on the use of a scoring system in determining a positive ultrasound were limited to two studies.[29,31]

### 4. Sensitivity Analysis

In the sensitivity analysis, studies with high risk of bias showed a higher sensitivity (Sn 0.97, 95% CI 0.89, 0.99) compared to the overall estimates (Sn 0.93, 95% CI 86, 97). Most of these studies had patient selection bias. Studies with unclear risk of bias showed a lower sensitivity (Sn 0.83, 95% CI 0.69, 0.92). Most of these studies had observer bias.

### Common findings on ultrasound

Among the included studies, four have data on the common lung ultrasound findings [21,22,26,30]. Table 4 summarizes the abnormalities found on lung ultrasound imaging in individuals with COVID-19. The most common findings in lung ultrasound were the presence of B-lines, with little difference between confluent (42.7%) and isolated (38.2%) B-lines. Presence of consolidations were noted in two studies (23.3-31.7%). Other findings were pleural effusion (2 studies, 12.4-12.7%), irregular pleural lines (42.7%), pleural thickening (48.8%) and air bronchograms (27.0%) predominantly involving multiple lung lobes (54%).

Table 4. Common Findings on Lung Ultrasound

Lung ultrasound findings	No. of studies	Prevalence in studies	No. of reported cases	Total no. of patients	Percentage of patients
<b>FEATURES</b>					
<b>Presence of B-lines</b>	<b>4</b>	<b>38.2-69.8%</b>	<b>176</b>	<b>331</b>	<b>53.2%</b>
Confluent B-lines	1	42.7%	38	89	42.7%
Isolated B-lines	1	38.2%	34	89	38.2%
<b>Presence of consolidations</b>	<b>3</b>	<b>23.3-31.7%</b>	<b>55</b>	<b>195</b>	<b>28.2%</b>
<b>Pleural effusion</b>	<b>2</b>	<b>12.4-12.7%</b>	<b>19</b>	<b>152</b>	<b>12.5%</b>
<b>Irregular pleural lines</b>	<b>1</b>	<b>42.7%</b>	<b>38</b>	<b>89</b>	<b>42.7%</b>
<b>Pleural thickening</b>	<b>1</b>	<b>48.8%</b>	<b>21</b>	<b>43</b>	<b>48.8%</b>
<b>Air bronchogram</b>	<b>1</b>	<b>27.0%</b>	<b>17</b>	<b>63</b>	<b>27.0%</b>
<b>DISTRIBUTION OF LESIONS</b>					
<b>Laterality of lesion</b>					
Bilateral	3	28.1-76.6%	204	466	43.8%
<b>Lobar involvement</b>					
Multilobular	1	54.0%	34	63	54.0%
<b>Lobar predominance</b>					
Upper lobe	1	11.1%	7	63	11.1%
Middle lobe	1	9.5%	6	63	9.5%
Lower lobe	1	49.2%	31	63	49.2%



## **Chest Tomography Scan (CT Scan)**

### **A. Characteristics of Included Studies**

The diagnostic accuracy of CT scan was reported in 62 observational studies (two cross-sectional studies, seven prospective cohort studies, 52 retrospective cohort studies, and one case-control study) involving multiple countries with a total sample of 39,929.[9,18,24,30,32-33,35-90]. Twenty new studies were added in this review. Forty-five studies exclusively involved adult patients, three studies exclusively involved the pediatric population, while the rest of the studies have unspecified or mixed population characteristics. Majority of the studies involved symptomatic patients (40/62 studies, 65%). Thirty studies (48%) specified the use of chest CT scan in the emergency room setting. There were no studies with specific data on the vaccination status of patients or the predominant COVID-19 variant that was prevalent during the time of the study. All studies used RT-PCR as the reference standard for the diagnosis of COVID-19.

Experienced radiologists or readers were involved in the majority (39/62 or 63%) of the studies, while three studies involved inexperienced readers. The studies utilized varied standards to qualify for reader experience. For this review, experienced readers included consultants or experts in CT imaging evaluation, and readers with more than five years of experience. Readers with less than five years of experience, radiologists-in-training, and non-radiologist readers (i.e. radiographers) were tagged as inexperienced readers.

Majority of the studies were not able to describe the type of CT used, but some reported using non-contrast enhanced or plain (19 studies), contrast-enhanced (1 study), low-dose (8 studies), and high-resolution CT scans (5 studies). Twenty-seven studies relied on reader impression as an index of test positivity, while 35 studies used different scoring systems to ascertain the diagnosis of COVID-19. Scoring systems include COVID-19 Reporting and Data System (CO-RADS), CT Involvement Scores (CTIS), British Society of Thoracic Imaging (BTSI), chest CT scan severity score (CTSS), French Society of Radiology Criteria, and Radiology Society of North America (RSNA). A few used an unvalidated scoring system.

### **B. Overall certainty of evidence**

The overall certainty of evidence for the diagnostic accuracy of CT scan was very low. Serious risk of bias was noted due to unclear risk on all four appraisal domains (32 studies with unclear risk of bias and 28 studies with high risk of bias). The considerable heterogeneity led to a very serious inconsistency. Serious imprecision due to wide confidence interval values were also noted (See Appendix 4 for the Risk of Bias Ratings and Appendix 6 for the GRADE Evidence Profile).

### **C. Outcomes**

#### ***Diagnostic performance of CT scan***

The pooled sensitivity and specificity of CT scan in diagnosing COVID-19 was 85% (95% CI 0.81, 0.88) and 78% (95% CI 0.71, 0.84) respectively. Very high heterogeneity was observed across studies ( $I^2=100%$ ) possibly because of a number of factors including number of patients sampled per study, definition of index test positivity, and experience of readers. The previous review showed a sensitivity of 88% (95% CI 0.84, 0.90) and specificity of 80% (95% CI 0.74, 0.84).[91]

Results of the subgroup analyses are summarized in Table 5. Subgroup analysis based on population characteristics (i.e. severity of disease) was not possible due to lack of aggregated data. Table 5 describes the subgroup analyses based on presence of symptoms, timing of testing in relation to symptom onset, reader experience, category of index test positivity, types of CT scan used, and pediatric population.



## Philippine COVID-19 Living Clinical Practice Guidelines

Table 5. Subgroup analyses of the diagnostic accuracy of chest CT scan for detecting COVID-19 infection

Subgroups	No. of Studies	n	Sensitivity	95% CI	Specificity	95% CI
<b>Overall</b>	<b>62</b>	<b>39,929</b>	<b>0.85</b>	<b>0.81, 0.88</b>	<b>0.78</b>	<b>0.71, 0.84</b>
<b>Presence of Symptoms</b>						
Symptomatic	40	28,722	0.88	0.85, 0.91	0.78	0.71, 0.84
Mixed	14	9,162	0.75	0.65, 0.83	0.82	0.66, 0.91
<b>Reader Experience</b>						
Experienced	39	28,112	0.84	0.79, 0.87	0.79	0.68, 0.87
Inexperienced	3	5,785	0.74	0.57, 0.86	0.82	0.79, 0.85
<b>Timing of Testing in Relation to Symptom Onset</b>						
Late	1	3,141	0.88	0.87, 0.89	0.65	0.59, 0.71
Mixed	15	13,638	0.88	0.84, 0.92	0.80	0.69, 0.87
<b>Category of Index Test Positivity</b>						
Reader impression	27	17,184	0.87	0.80, 0.91	0.70	0.55, 0.82
Scoring system	35	22,745	0.84	0.79, 0.87	0.83	0.77, 0.87
<b>Type of CT scan Used</b>						
Non-contrast enhanced	19	10,420	0.84	0.78, 0.88	0.83	0.67, 0.92
Contrast-enhanced	1	694	0.90	0.86, 0.93	0.88	0.84, 0.91
High resolution (HRCT)	5	11,891	0.88	0.76, 0.94	0.70	0.42, 0.88
Low-dose	8	1,438	0.89	0.78, 0.94	0.78	0.69, 0.85
<b>Others (special groups)</b>						
Pediatric population	4	371	0.53	0.34, 0.71	0.60	0.23, 0.88
<b>Sensitivity Analysis</b>						
High risk of bias	28	12,849	0.87	0.84, 0.90	0.82	0.77, 0.87
Unclear risk of bias	32	26,749	0.82	0.76, 0.88	0.75	0.61, 0.85
Low risk of bias	2	331	0.90	0.55, 0.98	0.52	0.39, 0.64

### 1. Presence of Symptoms

No specific data were available on the use of chest CT scan for asymptomatic individuals. However, studies with both symptomatic and asymptomatic individuals showed a lower sensitivity of chest CT scan (Sn 0.75, 95% CI 0.65, 0.83) compared to symptomatic individuals alone (Sn 0.88, 95% CI 0.85, 0.91).

### 2. Reader Experience

Sensitivity was higher in experienced readers (Sn 0.84, 95%CI 0.79, 0.87) than inexperienced readers (Sn 0.74, 95% CI 0.57, 0.86). Specificity was higher in inexperienced readers (Sp 0.82, 95% CI 0.79, 0.85). However, data on inexperienced readers are limited.

### 3. Timing of Testing in Relation to Symptom Onset

Only one study described the diagnostic accuracy of chest CT scan based on the timing of testing in relation to symptom onset.[80] This study showed that sensitivity was 0.88 (95% CI 0.87, 0.89) when chest CT scan was done five days after symptom onset. This is similar to the sensitivity found in studies that performed the chest CT scan at both early and late timing (up to 14 days) in relation to symptom onset (Sn 0.88, 95% CI 0.84, 0.92; 15 studies). However, data remains limited.



## Philippine COVID-19 Living Clinical Practice Guidelines

### 4. Index Test Positivity

Using a scoring system to determine a positive CT scan showed comparable sensitivity with a reader's impression (Sn 0.84 vs. Sn 0.87). Specificity was higher (Sp 0.83, 95% CI 0.77, 0.87) with the use of a scoring system.

### 5. Type of CT scan used

Studies that used contrast-enhanced CT scan (Sn 0.90, 95% CI 0.86, 0.93; 1 study), high resolution CT scan (Sn 0.88, 95% CI 0.76, 0.94; 5 studies), and low-dose CT scan (Sn 0.89, 95% CI 0.78, 0.94; 8 studies) demonstrated higher sensitivity than studies that used plain/non-contrast enhanced CT scan (Sn 0.84, 95% CI 0.78, 0.88; 19 studies). However, there were only a few studies on this.

### 6. Pediatric Population

Four studies were conducted among the pediatric population.[37,60,77,84] Sensitivity of CT scan in children was 0.53 (95% CI 0.34, 0.71) while specificity was 0.6 (95% CI 0.23, 0.88).

### 7. Sensitivity Analysis

Studies with low risk of bias showed increased sensitivity (Sn 0.90, 95% CI 0.55, 0.98) compared to the overall sensitivity (Sn 0.85, 95%CI 0.81, 0.88). However, this was limited to two studies only. A higher sensitivity was also seen in studies with high risk of bias (Sn 0.87, 95% CI 0.84, 0.90). These studies have patient selection bias and observer bias. Studies with unclear risk of bias lead to a lower sensitivity (Sn 0.82, 95% CI 0.76, 0.88).

### Common findings on CT scan

Among the included studies, 20 have data on the common findings of COVID-19 on chest CT scan.[18,24,30,35-37,43,45,52,53,60,65-68,79,72,75,81] Two studies on the pediatric population described the common chest CT findings in children. Overall, the most common CT scan finding was ground glass opacities (20 studies, 9.5-90.4%) with 2,097 total reported cases among COVID-19 patients. This finding is consistent among the pediatric population (2 studies, 9.5-31.5%). Other common findings were consolidation pneumonia (16 studies, 1.4-70.4%) and a description of crazy paving patterns (8 studies, 6.7-71.1%). Distribution of lesions were found to be located more on the periphery (11 studies, 16.2-79.5%) than in central/perihilar regions (7 studies, 1.7-60.2%), involved both lungs (12 studies, 6.1-73.4%), and involved multiple lobes (7 studies, 8.8-66.7%). These and other findings are summarized in Table 6.

Table 6. Abnormalities found on CT scan among Individuals with COVID-19

CT scan findings	No. of studies	Prevalence in studies	No. of reported cases	Total no. of patients	Percentage of patients
<b>FEATURES</b>					
Ground glass opacities	20	9.5-90.4%	2,097	4,749	44.2%
Ground glass opacities with consolidation	8	1.5-38.4%	191	954	20.0%
Consolidation	16	1.4-70.4%	1,356	4,198	32.3%
Crazy paving pattern	8	6.7-71.1%	469	2,234	21.0%
Air bronchogram	6	0.2-39.6%	152	1,380	11.0%
Vascular enlargement	8	5.4-43.5%	272	1,646	16.5%
Interlobular septal wall thickening	5	0.8-54.0%	96	1,497	6.4%
Halo sign	7	0.4-10.8%	40	1,311	3.1%
Nodules	7	1.4-17.8%	118	2,139	5.5%
Lymphadenopathy	9	0.7-21.5%	169	2,147	7.9%
Pleural effusion	12	0.7-15.9%	143	2,447	5.8%



## Philippine COVID-19 Living Clinical Practice Guidelines

CT scan findings	No. of studies	Prevalence in studies	No. of reported cases	Total no. of patients	Percentage of patients
<b>DISTRIBUTION OF LESIONS</b>					
<b>Predominant distribution</b>					
Central/perihilar	7	1.7-60.2%	183	1,278	14.3%
Peripheral	11	16.2-79.5%	964	1,971	48.9%
<b>Laterality of lesion</b>					
Bilateral	12	6.1-73.4%	1,258	2,605	48.3%
Unilateral	4	0.9-7.9%	41	977	4.2%
<b>Lobar involvement</b>					
Unilobular	4	0.5-46.6%	54	910	5.9%
Multilobular	7	8.8-66.7%	497	1,219	40.8%
<b>FEATURES (PEDIATRIC PATIENTS)</b>					
Ground glass opacities	2	9.5-31.5%	42	237	17.7%
Ground glass opacities with consolidation	1	4.1%	6	148	4.1%
Consolidation	2	2.0-9.0%	11	237	4.6%
Vascular enlargement	2	5.4-10.1%	17	237	7.2%
Halo sign	2	2.2-5.4%	10	237	4.2%
Nodules	1	1.4%	2	148	1.4%
Lymphadenopathy	1	0.7%	1	148	0.7%
Pleural effusion	1	0.7%	1	148	0.7%
<b>DISTRIBUTION OF LESIONS (PEDIATRIC PATIENTS)</b>					
<b>Predominant distribution</b>					
Central/perihilar	1	5.6%	5	89	5.6%
Peripheral	1	33.7%	30	89	33.7%
<b>Laterality of lesion</b>					
Bilateral	1	6.1%	9	148	6.1%
Unilateral	1	9.5%	14	148	9.5%
<b>Lobar involvement</b>					
Unilobular	1	6.6%	10	148	6.8%
Multilobular	1	8.8%	13	148	8.8%

### Other Considerations

The usual cost of the three imaging modalities are listed in Table 7. Chest x-ray ranges from Php 250 to Php 1,450. Lung ultrasound ranges from Php 360 to 2,500. Chest CT scan ranges from Php 2,600 to 12,700. These prices do not include the additional costs for physical protective equipment and will vary per institution.

Table 7. Prices of Chest Imaging Modalities in the Philippines

	Chest X-Ray	Lung Ultrasound	CT scan
Government	Adult: Php 250-530 Child: Php 260-550	Php 360-640	High Resolution: Php 4,000-5,500 Plain: Php 2,650-Php 3,000 Contrast-enhanced: Php 7,340
Private	PA: Php 350 PA/L: Php 690-1459.20 Child: Php 480	Php 1,000-2,582	Plain: Php 3,550-12,702.45

In Canada, a cost-benefit analysis study on the use of portable chest radiography through glass during the COVID-19 pandemic was done. The results showed a net benefit of 9.87 USD per patient imaged and a projected net cost saving of 51, 451.84 USD per year.[92] In the Philippines,



## Philippine COVID-19 Living Clinical Practice Guidelines

there is no local data on the economic evaluation on the use of chest x-ray, lung ultrasound, and chest CT scan for the diagnosis of COVID-19.

### Recommendations from Other Groups

#### **World Health Organization (June 11, 2020) [93]**

The World Health Organization (WHO) suggests against the use of chest imaging (including chest x-ray, lung ultrasound, and CT scan) in COVID-19 for symptomatic patients when RT-PCR testing is available with timely results. RT-PCR should be done to confirm the diagnosis of COVID-19 (Low certainty of evidence; conditional recommendation). However, WHO suggests using chest imaging (with no preference to one specific imaging modality) for the diagnostic workup of COVID-19 when: (1) RT-PCR testing is not available; (2) RT-PCR testing is available, but results are delayed; and (3) initial RT-PCR testing is negative, but with high clinical suspicion of COVID-19 (Low certainty of evidence, conditional recommendation). Chest imaging should be used in conjunction with clinical and laboratory data.

#### **Philippine Pediatric Society & Pediatric Infectious Disease Society of the Philippines (February 6, 2021) [94]**

According to the Philippine Pediatric Society, ancillary laboratory tests may aid in (1) screening and triaging of children presenting with symptoms, and (2) assessing the severity of symptoms and need for further management. If either exposure evaluation, clinical evaluation, or ancillary laboratory tests (particularly imaging procedures) is positive, the diagnosis of COVID-19 should be considered.

Chest x-ray is the recommended first line imaging modality in children suspected to have COVID-19 presenting with respiratory symptoms. However, this modality has limited sensitivity and specificity. Hence, a negative chest x-ray does not exclude pulmonary involvement in patients with laboratory-confirmed COVID-19, nor does it indicate absence of infection in cases of suspected COVID-19 not yet confirmed by RT-PCR.

Chest CT scan is not recommended as the initial diagnostic test in pediatric patients suspected to have COVID-19. Chest CT scan findings of COVID-19 in the pediatric population are not pathognomonic but may be suggestive of the diagnosis in the appropriate clinical setting. It may be considered in patients with a worsening clinical course who are not responding appropriately to therapy, or to further investigate a specific pulmonary condition.

Chest ultrasound has been used as an alternative to chest x-ray and chest CT scan in the diagnosis of pneumonia in COVID-19 patients due to its ease of use at point-of-care, absence of radiation exposure, and lower cost than CT scan. No specific recommendation is given for chest ultrasound.

#### **US Centers for Disease Control (CDC) (February 16, 2021) [95]**

The Centers for Disease Control (CDC) does not recommend CXR or CT to diagnose COVID-19. Viral testing remains the only specific method of diagnosis. Confirmation with the viral test is required, even if radiologic findings are suggestive of COVID-19 on CXR or CT.

#### **American College of Radiology (ACR) (March 22, 2020) [96]**

The American College of Radiology recommends against the use of CT scan as a first-line test to diagnose COVID-19. CT should be used sparingly and reserved for hospitalized, symptomatic patients with specific clinical indications for CT.



## Ongoing Studies

There are eight ongoing studies (four on chest CT scan, one chest x-ray and two lung ultrasound) registered at [clinicaltrials.gov](https://clinicaltrials.gov).<sup>[97-104]</sup> These studies are on the use of thoracic imaging in the diagnosis of COVID-19 in suspected individuals with RT PCR as the reference standard. (See Appendix 7 for details on Ongoing Studies).





### References

- [1] Islam N, Ebrahimzadeh S, Salameh JP, Kazi S, Fabiano N, Treanor L, et al. Thoracic imaging tests for the diagnosis of COVID-19. *Cochrane Database Syst Rev.* 2021;2021(3). doi: 10.1002/14651858.CD013639.pub4
- [2] Akl EA, Blazic I, Yaacoub S, Frijia G, Chou R, Appiah JA, et al. Use of Chest Imaging in the Diagnosis and Management of COVID-19: A WHO Rapid Advice Guide. *Radiology.* 2021;298(2):E63–9. doi: 10.1148/RADIOL.2020203173
- [3] Churruca M, Martínez-Besteiro E, Couñago F, Landete P. COVID-19 pneumonia: A review of typical radiological characteristics. *World J Radiol [Internet].* 2021 Oct 28;13(10):327–43. Available from: <https://www.wjgnet.com/1949-8470/full/v13/i10/327.htm>
- [4] Liu J, Yang X, Zhu Y, Zhu Y, Liu J, Zeng X, et al. Diagnostic value of chest computed tomography imaging for COVID-19 based on reverse transcription-polymerase chain reaction: a meta-analysis. *Infect Dis Poverty [Internet].* 2021;10(1):1–10. Available from: <https://doi.org/10.1186/s40249-021-00910-8>
- [5] San Jose MC, Dones V. Should Chest x-ray be done to diagnose COVID-19 among suspected patients? Evidence Summary [Internet]. *Psmid.org.* 2021 [cited 2021 Dec 7]. Available from: <https://www.psmid.org/chest-x-ray-evidence-summary/>
- [6] Martínez Redondo J, Comas Rodríguez C, Pujol Salud J, Crespo Pons M, García Serrano C, Ortega Bravo M, et al. Higher accuracy of lung ultrasound over chest X-ray for early diagnosis of COVID-19 pneumonia. *Int J Environ Res Public Health [Internet].* 2021;18(7):3481. Available from: <http://dx.doi.org/10.3390/ijerph18073481>
- [7] Tsou P-Y, Chen KP, Wang Y-H, Fishe J, Gillon J, Lee C-C, et al. Diagnostic accuracy of lung ultrasound performed by novice versus advanced sonographers for pneumonia in children: A Systematic Review and meta-analysis. *Acad Emerg Med [Internet].* 2019;26(9):1074–88. Available from: <http://dx.doi.org/10.1111/acem.13818>
- [8] Cellina M, Martinenghi C, Marino P, Oliva G. COVID-19 pneumonia-ultrasound, radiographic, and computed tomography findings: a comprehensive pictorial essay. *Emerg Radiol [Internet].* 2021;28(3):519–26. Available from: <http://dx.doi.org/10.1007/s10140-021-01905-6>
- [9] Borakati A, Perera A, Johnson J, Sood T. Diagnostic accuracy of X-ray versus CT in COVID-19: A propensity-matched database study. *BMJ Open.* 2020;10(11):1–14. doi: 10.1136/bmjopen-2020-042946
- [10] Roy Choudhury SH, Shahi PK, Sharma S, Dhar R. Utility of chest radiography on admission for initial triaging of COVID-19 in symptomatic patients. *ERJ Open Res [Internet].* 2020;6(3):00357–2020. Available from: <http://dx.doi.org/10.1183/23120541.00357-2020>
- [11] Cozzi A, Schiaffino S, Arpaia F, Della Pepa G, Tritella S, Bertolotti P, et al. Chest x-ray in the COVID-19 pandemic: Radiologists' real-world reader performance. *Eur J Radiol [Internet].* 2020 Nov;132(January):109272. Available from: <https://linkinghub.elsevier.com/retrieve/pii/S0720048X20304617>
- [12] Du R, Tsougenis ED, Ho JWK, Chan JKY, Chiu KWH, Fang BXH, et al. Machine learning application for the prediction of SARS-CoV-2 infection using blood tests and chest radiograph. *Sci Rep [Internet].* 2021;11(1):1–13. Available from: <https://doi.org/10.1038/s41598-021-93719-2>
- [13] Gibbons RC, Magee M, Goett H, Murrett J, Genninger J, Mendez K, et al. Lung Ultrasound vs. Chest X-Ray Study for the Radiographic Diagnosis of COVID-19 Pneumonia in a High-Prevalence Population. In: *Journal of Emergency Medicine.* 2021. p. 615–25. doi: 10.1016/j.jemermed.2021.01.041
- [14] Gichoya JW, Sinha P, Davis M, Dunkle JW, Hamlin SA, Herr KD, et al. Multireader evaluation of radiologist performance for COVID-19 detection on emergency department chest radiographs. *Clin Imaging [Internet].* 2021;82(May 2021):77–82. Available from: <https://doi.org/10.1016/j.clinimag.2021.10.018>



## Philippine COVID-19 Living Clinical Practice Guidelines

- [15] Hwang EJ, Kim H, Yoon SH, Goo JM, Park CM. Implementation of a deep learning-based computeraided detection system for the interpretation of chest radiographs in patients suspected for covid-19. *Korean J Radiol.* 2020;21(10):1150–60.
- [16] Hwang EJ, Kim KB, Kim JY, Lim JK, Nam JG, Choi H, et al. COVID-19 pneumonia on chest X-rays: Performance of a deep learning-based computer-aided detection system. *PLoS One* [Internet]. 2021;16(6 June):1–16. Available from: <http://dx.doi.org/10.1371/journal.pone.0252440>
- [17] Ippolito D, Pecorelli A, Maino C, Capodaglio C, Mariani I, Giandola T, et al. Diagnostic impact of bedside chest X-ray features of 2019 novel coronavirus in the routine admission at the emergency department: case series from Lombardy region. *Eur J Radiol* [Internet]. 2020;129(May):109092. Available from: <https://doi.org/10.1016/j.ejrad.2020.109092>
- [18] Khan SA, Manohar M, Khan M, Asad S, Adil SO. Radiological profile of patients undergoing chest x-ray and computed tomography scans during covid-19 outbreak. *Pakistan J Med Sci.* 2021;37(5):1288–94. doi: 10.12669/pjms.37.5.4290
- [19] Majeed AI, Raza F, Riaz SK, Kanwal J. The Essential Role Of Conventional Radiography In Covid-19; Perspective Of A Developing Country. *J Ayub Med Coll Abbottabad.* 2021;33(2):267–73.
- [20] Murphy K, Smits H, Knoop AJG, Korst MBJM, Samson T, Scholten ET, et al. COVID-19 on chest radiographs: A multireader evaluation of an artificial intelligence system. *Radiology.* 2020;296(3):E166–72. doi: 10.1148/radiol.2020201874
- [21] Pare JR, Camelo I, Mayo KC, Leo MM, Dugas JN, Nelson KP, et al. Point-of-care lung ultrasound is more sensitive than chest radiograph for evaluation of COVID-19. *West J Emerg Med.* 2020;21(4):771–8. doi: 10.5811/westjem.2020.5.47743
- [22] Peyrony O, Marbeuf-Gueye C, Truong V, Giroud M, Rivière C, Khenissi K, et al. Accuracy of Emergency Department Clinical Findings for Diagnosis of Coronavirus Disease 2019. *Ann Emerg Med* [Internet]. 2020 Oct;76(4):405–12. Available from: <https://www.ncbi.nlm.nih.gov/pmc/articles/PMC7254017/pdf/main.pdf>
- [23] Schiaffino S, Tritella S, Cozzi A, Carriero S, Blandi L, Ferraris L, et al. Diagnostic Performance of Chest X-Ray for COVID-19 Pneumonia during the SARS-CoV-2 Pandemic in Lombardy, Italy. *J Thorac Imaging.* 2020;35(4):W105–6. doi: 10.1097/RTI.0000000000000533
- [24] Stephanie S, Shum T, Cleveland H, Challa SR, Herring A, Jacobson FL, et al. Determinants of chest radiography sensitivity for covid-19: A multi-institutional study in the United States. *Radiol Cardiothorac Imaging.* 2020;2(5). doi: 10.1148/ryct.2020200337
- [25] Stevens BJ. Reporting radiographers' interpretation and use of the British Society of Thoracic Imaging's coding system when reporting COVID-19 chest x-rays. *Radiography.* 2021;27(1):90–4. doi: 10.1016/j.radi.2020.06.010
- [26] Tung-Chen Y, Algora-Martín A, Llamas-Fuentes R, Rodríguez-Fuertes P, Martínez Virto AM, Sanz-Rodríguez E, et al. Point-of-care ultrasonography in the initial characterization of patients with COVID-19. *Med Clin (Barc).* 2021;156(10):477–84. doi: 10.1016/j.medcli.2020.12.007
- [27] Bar S, Lecourtois A, Diouf M, Goldberg E, Bourbon C, Arnaud E, et al. The association of lung ultrasound images with COVID-19 infection in an emergency room cohort. *Anaesthesia.* 2020;75(12):1620–5. doi: 10.1111/anae.15175
- [28] Bitar ZI, Shamsah M, Maadarani OS, Bamasood OM, Al-foudari H. Appropriateness of lung ultrasound for the diagnosis of COVID -19 pneumonia . *Heal Sci Reports.* 2021;4(2):1–7. doi: 10.1002/hsr2.302
- [29] Dini FL, Bergamini C, Allegrini A, Scopelliti M, Secco G, Miccoli M, et al. Bedside wireless lung ultrasound for the evaluation of COVID-19 lung injury in senior nursing home residents. *Monaldi Arch Chest Dis.* 2020;90(3):523–7. doi: 10.4081/monaldi.2020.1446
- [30] Fonsi GB, Sapienza P, Brachini G, Andreoli C, De Cicco ML, Cirillo B, et al. Is Lung Ultrasound Imaging a Worthwhile Procedure for Severe Acute Respiratory Syndrome Coronavirus 2 Pneumonia Detection? *J Ultrasound Med.* 2021;40(6):1113–23. doi: 10.1002/jum.15487



## Philippine COVID-19 Living Clinical Practice Guidelines

- [31] Haak SL, Renken IJE, Jager LC, Lameijer H, Van Der Kolk BBYM. Diagnostic accuracy of point-of-care lung ultrasound in COVID-19. *Emerg Med J*. 2021;38(2):94–9. doi: 10.1136/emmermed-2020-210125
- [32] Lieveeld AWE, Kok B, Schuit FH, Azijli K, Heijmans J, van Laarhoven A, et al. Diagnosing COVID-19 pneumonia in a pandemic setting: Lung Ultrasound versus CT (LUVCT) – a multicentre, prospective, observational study. *ERJ Open Res* [Internet]. 2020;6(4):00539–2020. Available from: <http://dx.doi.org/10.1183/23120541.00539-2020>
- [33] Narinx N, Smismans A, Symons R, Frans J, Demeyere A, Gillis M. Feasibility of using point-of-care lung ultrasound for early triage of COVID-19 patients in the emergency room. *Emerg Radiol*. 2020;27(6):663–70. doi: 10.1007/s10140-020-01849-3
- [34] Burog AIL, Cabaluna IT, Bayona HH. Should lung ultrasound alone be used to diagnose COVID-19 infection among suspected patients? Evidence Summary [Internet]. Psmid.org. 2021 [cited 2021 Dec 9]. Available from: <https://www.psmid.org/lung-ultrasound-evidence-summary/>
- [35] Ai T, Yang Z, Hou H, et al. Correlation of chest CT and RT-PCR testing for coronavirus disease 2019 (COVID-19) in China: a report of 1014 cases. *Radiology* 2020;296:E32-E40. doi: 10.1148/radiol.2020200642
- [36] Aslan S, Becki T, Cakir I, Ekiz M, Yavuz I, Sahin A. Diagnostic performance of low-dose chest CT to detect COVID-19: A Turkish population study. *Diagn Interv Radiol* 2021;27:181-7. doi: 10.5152/dir.2020.20350
- [37] Bağcı Z, Keçeli AM. Comparison of computed tomography (CT) findings with RT-PCR in the diagnosis of COVID-19 in children. *Pediatr Pulmonol*. 2021;56(7):1985–91. doi: 10.1002/ppul.25426
- [38] Barbosa P, Bitencourt A, Miranda Gd, Almeida M, Chonjniak R. Chest CT accuracy in the diagnosis of SARS-CoV-2 infection: initial experience in a cancer center. *Radiol Bras* 2020;53:211-5. doi: 10.1590/0100-3984.2020.0040
- [39] Bellini D, Panvini N, Rengo M, Vicini S, Lichtner M, Tieghi T, et al. Diagnostic accuracy and interobserver variability of CO-RADS in patients with suspected coronavirus disease-2019: a multireader validation study. *Eur Radiol*. 2021;31(4):1932–40.
- [40] Berkel B Van, Vandevenne J, Coursier K, Alberts V, Offenwert J Van, Verduyck J, et al. Chest CT Diagnosis of COVID-19: Accuracy using CO-RADS and CT-Involvement Scoring. *J Belgian Soc Radiol*. 2021;105(1):1–7. doi: 10.5334/JBSR.2342
- [41] Besutti G, Giorgi Rossi P, Iotti V, Spaggiari L, Bonacini R, Nitrosi A, et al. Accuracy of CT in a cohort of symptomatic patients with suspected COVID-19 pneumonia during the outbreak peak in Italy. *Eur Radiol*. 2020;30(12):6818–27. doi: 10.1007/s00330-020-07050-x
- [42] Gaia C, Maria Chiara C, Silvia L, Chiara A, Maria Luisa DC, Giulia B, et al. Chest CT for early detection and management of coronavirus disease (COVID-19): a report of 314 patients admitted to Emergency Department with suspected pneumonia. *Radiol Medica* [Internet]. 2020;125(10):931–42. Available from: <https://doi.org/10.1007/s11547-020-01256-1>
- [43] Caruso D, Zerunian M, Polici M, Pucciarelli F, Polidori T, Rucci C, et al. Chest CT Features of COVID-19 in Rome, Italy. *Radiology*. 2020;296(2):E79–85. doi: 10.1148/radiol.2020201237
- [44] de Smet K, de Smet D, Ryckaert T, Laridon E, Heremans B, Vandebulcke R, et al. Diagnostic performance of chest CT for SARS-CoV-2 infection in individuals with or without COVID-19 symptoms. *Radiology*. 2020;298(1):E30–7. doi: 10.1148/RADIOL.2020202708
- [45] Debray MP, Tarabay H, Males L, Chalhoub N, Mahdjoub E, Pavlovsky T, et al. Observer agreement and clinical significance of chest CT reporting in patients suspected of COVID-19. *Eur Radiol*. 2021;31(2):1081–9. doi: 10.1007/s00330-020-07126-8
- [46] Deng Z, Zhange X, Li Y, Xu H, Gang Y, Wang H. Value of chest CT screening in the early COVID-19 outbreak. *Chinese Journal of Radiology* 2020;54:30-4. doi: 10.3760/cma.j.cn112149-20200218-00187



## Philippine COVID-19 Living Clinical Practice Guidelines

- [47] Dofferhoff A, Swinkels A, Sprong T, Berk Y, Spanbroek M, Nabuurs-Franssen M. Diagnostic algorithm for COVID-19 at the ER. *Nederlands Tidschrift voor Geneeskunde* 2020;164:D5042.
- [48] Ducray V, Vlachomitrou AS, Bouscambert-Duchamp M, Si-Mohamed S, Gouttard S, Mansuy A, et al. Chest CT for rapid triage of patients in multiple emergency departments during COVID-19 epidemic: experience report from a large French university hospital. *Eur Radiol.* 2021;31(2):795–803. doi: 10.1007/s00330-020-07154-4
- [49] Falaschi Z, Danna PSC, Arioli R, Pasché A, Zagaria D, Percivale I, et al. Chest CT accuracy in diagnosing COVID-19 during the peak of the Italian epidemic: A retrospective correlation with RT-PCR testing and analysis of discordant cases. *Eur J Radiol* [Internet]. 2020 Sep;130(January):109192. Available from: <https://linkinghub.elsevier.com/retrieve/pii/S0720048X20303818>
- [50] Fujioka T, Takahashi M, Mori M, Tsuchiya J, Yamaga E, Horii T, et al. Evaluation of the Usefulness of CO-RADS for Chest CT in Patients Suspected of Having COVID-19. *Diagnostics.* 2020;10(9). doi: 10.3390/diagnostics10090608
- [51] Gezer NS, Ergan B, Barış MM, Appak Ö, Sayiner AA, Balcı P, et al. Covid-19 s: A new proposal for diagnosis and structured reporting of covid-19 on computed tomography imaging. *Diagnostic Interv Radiol.* 2020;26(4):315–22. doi: 10.5152/dir.2020.20351
- [52] Giannitto C, Sposta FM, Repici A, Vatteroni G, Casiraghi E, Casari E, et al. Chest CT in patients with a moderate or high pretest probability of COVID-19 and negative swab. *Radiol Medica* [Internet]. 2020;125(12):1260–70. Available from: <https://doi.org/10.1007/s11547-020-01269-w>
- [53] Gietema HA, Zelis N, Nobel JM, Lambriksi LJG, Alphen LBV, Lashof AMLO, et al. CT in relation to rt-PCR in diagnosing covid-19 in the netherlands: A prospective study. *PLoS One* [Internet]. 2020;15(7 July):1–10. Available from: <http://dx.doi.org/10.1371/journal.pone.0235844>
- [54] Grando RD, Brentano VB, Zanardo AP, Hertz FT, Júnior LCA, Prietto dos Santos JF, et al. Clinical usefulness of tomographic standards for COVID-19 pneumonia diagnosis: Experience from a Brazilian reference center. *Brazilian J Infect Dis* [Internet]. 2020 Nov;24(6):524–33. Available from: <https://linkinghub.elsevier.com/retrieve/pii/S1413867020301471>
- [55] Guillo E, Bedmar Gomez I, Dangeard S, Bennani S, Saab I, Tordjman M, et al. COVID-19 pneumonia: Diagnostic and prognostic role of CT based on a retrospective analysis of 214 consecutive patients from Paris, France. *Eur J Radiol* [Internet]. 2020 Oct;131(January):109209. Available from: <https://linkinghub.elsevier.com/retrieve/pii/S0720048X20303983>
- [56] He J, Luo L, Luo Z, Lyu J, Ng M, Shen X, et al. Diagnostic performance between CT and initial real-time RT-PCR for clinically suspected 2019 coronavirus disease (COVID-19) patients outside Wuhan, China. *Respir Med* [Internet]. 2020 Jul;168(January):105980. Available from: <https://linkinghub.elsevier.com/retrieve/pii/S0954611120301207>
- [57] Hermans JJR, Groen J, Zwets E, Boxma-De Klerk BM, Van Werkhoven JM, Ong DSY, et al. Chest CT for triage during COVID-19 on the emergency department: myth or truth? *Emerg Radiol.* 2020;27(6):641–51.
- [58] Hernigou J, Cornil F, Poignard A, El Bouchaibi S, Mani J, Naouri JF, et al. Thoracic computerised tomography scans in one hundred eighteen orthopaedic patients during the COVID-19 pandemic: identification of chest lesions; added values; help in managing patients; burden on the computerised tomography scan department. *Int Orthop.* 2020;44(8):1571–80. doi: 10.1007/s00264-020-04651-5
- [59] Herpe G, Lederlin M, Naudin M, Ohana M, Chaumoitre K, Gregory J, et al. Efficacy of Chest CT for COVID-19 Pneumonia Diagnosis in France. *Radiology* [Internet]. 2021 Feb;298(2):E81–7. Available from: <http://pubs.rsna.org/doi/10.1148/radiol.2020202568>
- [60] Kalin S. Evaluation of Radiological Findings in Pediatric Patients with COVID-19 in Turkey. *North Clin Istanbul.* 2021;8(4):332–9. doi: 10.14744/nci.2020.97947
- [61] Kavak S, Duymus R. RSNA and BSTI grading systems of COVID-19 pneumonia: comparison of the diagnostic performance and interobserver agreement. *BMC Med Imaging* [Internet]. 2021;21(1). Available from: <https://doi.org/10.1186/s12880-021-00668-3>



## Philippine COVID-19 Living Clinical Practice Guidelines

- [62] Kızıloglu I, Sener A, Siliv N. Comparison of rapid antibody test and thorax computed tomography results in patients who underwent RT-PCR with the pre-diagnosis of COVID-19. *Int J Clin Pract*. 2021;(February):1–7. doi: 10.1111/ijcp.14524
- [63] Korevaar DA, Kootte RS, Smits LP, van den Aardweg JG, Bonta PI, Schinkel J, et al. Added value of chest computed tomography in suspected COVID-19: An analysis of 239 patients. *Eur Respir J*. 2020;56(2):38–41. doi: 10.1183/13993003.01377-2020
- [64] Krdzalic J, de Jaegere TMH, Kwee RM. Diagnostic performance of chest CT in screening patients with suspected COVID-19 infection in a Western population. *Br J Radiol [Internet]*. 2020 Sep 1;93(1113):20200643. Available from: <https://www.birpublications.org/doi/10.1259/bjr.20200643>
- [65] Kuzan TY, Murzoğlu Altıntoprak K, Çiftçi HÖ, Ergül U, Ünal Özdemir NB, Bulut M, et al. A comparison of clinical, laboratory and chest CT findings of laboratory-confirmed and clinically diagnosed COVID-19 patients at first admission. *Diagn Interv Radiol*. 2021;27(3):336–43. doi: 10.5152/dir.2020.20270
- [66] Li Z, Zeng B, Lei P, Liu J, Fan B, Shen Q, et al. Differentiating pneumonia with and without COVID-19 using chest CT images: from qualitative to quantitative. *J Xray Sci Technol*. 2020;28(4):583–9. doi: 10.3233/xst-200689
- [67] Luo L, Luo Z, Jia Y, Zhou C, He J, Lyu J, et al. CT differential diagnosis of COVID-19 and non-COVID-19 in symptomatic suspects: A practical scoring method. *BMC Pulm Med*. 2020;20(1):1–9. doi: 10.1186/s12890-020-1170-6
- [68] Luo N, Zhang H, Zhou Y, Kong ZX, Sun WH, Huang N, et al. Utility of chest CT in diagnosis of COVID-19 pneumonia. *Diagnostic Interv Radiol*. 2020;26(5):437–42. doi: 10.5152/dir.2020.20144
- [69] Mei X, Lee HC, Diao Kyue, Huang M, Lin B, Liu C, et al. Artificial intelligence-enabled rapid diagnosis of patients with COVID-19. *Nat Med [Internet]*. 2020;26(8):1224–8. Available from: <http://dx.doi.org/10.1038/s41591-020-0931-3>
- [70] Mirahmadizadeh A, Pourmontaseri Z, Afrashteh S, Hosseinzadeh M, Karimi J, Sharafi M. Sensitivity and specificity of chest computed tomography scan based on RT-PCR in COVID-19 diagnosis. *Polish J Radiol*. 2021;86:e74–7. doi: 10.5114/pjr.2021.103858
- [71] Miranda Magalhães Santos JM, Paula Alves Fonseca A, Pinheiro Zarattini Anastacio E, Formagio Minenelli F, Furtado De Albuquerque Cavalcanti C, Borges Da Silva Teles G. Initial results of the use of a standardized diagnostic criteria for chest computed tomography findings in coronavirus disease 2019. *J Comput Assist Tomogr*. 2020;44(5):647–51. doi: 10.1097/RCT.0000000000001054
- [72] Nair AV, McInnes M, Jacob B, Kumar D, Soman DK, Subair HSV, et al. Diagnostic accuracy and inter-observer agreement with the CO-RADS lexicon for CT chest reporting in COVID-19. *Emerg Radiol*. 2021;28(6):1045–54. doi: 10.1007/s10140-021-01967-6
- [73] Ohana M, Muller J, Severac F, Bilbault P, Behr M, Oberlin M, et al. Temporal variations in the diagnostic performance of chest CT for Covid-19 depending on disease prevalence: Experience from North-Eastern France. *Eur J Radiol [Internet]*. 2021 Jan;134(January):109425. Available from: <https://linkinghub.elsevier.com/retrieve/pii/S0720048X2030615X>
- [74] Özer H, Kılınçer A, Uysal E, Yormaz B, Cebeci H, Durmaz MS, et al. Diagnostic performance of Radiological Society of North America structured reporting language for chest computed tomography findings in patients with COVID-19. *Jpn J Radiol [Internet]*. 2021;39(9):877–88. Available from: <https://doi.org/10.1007/s11604-021-01128-2>
- [75] Özkarafulı MA, Özkurt H, Bardakçı Mİ, Akıllı IK, Yanç U, Altuntaş Y, et al. Comparison of chest computed tomography findings of RT-PCR negative and RT-PCR positive cases in COVID-19 patients. *Clin Imaging*. 2022;82(October 2021):7–12. doi: 10.1016/j.clinimag.2021.10.013
- [76] Patel M, Chowdhury J, Zheng M, Abramian O, Verga S, Zhao H. High resolution CHEST CT (HRCT) evaluation in patients hospitalized with COVID-19 infection. [Preprint] 2020. Available from: 10.1101/2020.05.26.20114082



## Philippine COVID-19 Living Clinical Practice Guidelines

- [77] Peng D, Zhang J, Xu Y, Liu Z, Wu P. The role of procalcitonin in early differential diagnosis of suspected children with COVID-19. [Preprint] 2020. Available from: <https://doi.org/10.1101/2020.04.07.20057315>
- [78] Prokop M, Van Everdingen W, Van Rees Vellinga T, Van Ufford HQ, Stöger L, Beenen L, et al. CO-RADS: A Categorical CT Assessment Scheme for Patients Suspected of Having COVID-19- Definition and Evaluation. *Radiology*. 2020;296(2):E97–104. doi: 10.1148/radiol.2020201473
- [79] Ravikanth R. Diagnostic accuracy of chest computed tomography in improving the false negative rate as compared to reverse transcriptase polymerase chain reaction in coronavirus disease 2019 pneumonia: A cross sectional analysis of 348 cases from India. *Lung India [Internet]*. 2021;38(7):11. Available from: <http://www.lungindia.com/text.asp?2021/38/7/11/310900>
- [80] Revel M, Boussouar S, de Margerie-Mellon C, Saab I, Lapotre T, Mompoin D, et al. Study of Thoracic CT in COVID-19: The STOIC Project. *Radiology [Internet]*. 2021 Oct;301(1):E361–70. Available from: <http://pubs.rsna.org/doi/10.1148/radiol.2021210384>
- [81] Saeed GA, Helali AA Al, Shah A, Almazrouei S, Ahmed LA. Chest CT performance and features of COVID-19 in the region of Abu Dhabi, UAE: a single institute study. *Chinese J Acad Radiol [Internet]*. 2021; Available from: <https://doi.org/10.1007/s42058-021-00075-1>
- [82] Schulze-Hagen M, Yüksel C, Sähn M, Isfort P, Kuhl C, Hübel C, et al. Low-dose chest CT for the diagnosis of COVID-19 a systematic, prospective comparison with PCR. *Dtsch Arztebl Int*. 2020;117(22–23):389–95. doi: 10.3238/arztebl.2020.0389
- [83] Shiota G, Sato Y, Itoh D, Gonoï W, Hayashi TY, Sugita Y, et al. Pitfalls in chest CT findings of COVID-19 patients infected during hospitalisation. *Clin Imaging*. 2021;78(January):146–53. doi: 10.1016/j.clinimag.2021.03.017
- [84] Simsek Yurt N, Ocak M, Yurt YC. Epidemiological and clinical characteristics of 3334 cases with prediagnosis coronavirus disease-2019 (COVID-19) in Turkey. *Int J Clin Pract*. 2021;75(10):1–8. doi: 10.1111/ijcp.14496
- [85] Song S, Wu F, Liu Y, Jiang H, Xiong F, Guo X, et al. Correlation between Chest CT Findings and Clinical Features of 211 COVID-19 Suspected Patients in Wuhan, China. *Open Forum Infect Dis*. 2020;7(6):1–8. doi: 10.1093/ofid/ofaa171
- [86] Steuwe A, Rademacher C, Valentin B, Köhler MH, Appel E, Keitel V, et al. Dose-optimised chest computed tomography for diagnosis of Coronavirus Disease 2019 (COVID-19) - Evaluation of image quality and diagnostic impact. *J Radiol Prot*. 2020;40(3):877–91. doi: 10.1088/1361-6498/aba16a
- [87] Thomas C, Naudin M, Tasu JP, Leclerc C, Depaire L, Suberville M, et al. Efficacy of chest CT scan for COVID-19 diagnosis in a low prevalence and incidence region. *Eur Radiol*. 2021;31(11):8141–6. doi: 10.1007/s00330-021-07863-4
- [88] Vicini S, Panvini N, Bellini D, Rengo M, Ciotola M, De Vivo M, et al. Radiographers and COVID-19 pneumonia: Diagnostic performance using CO-RADS. *Radiography [Internet]*. 2021 Nov;27(4):1078–84. Available from: <https://linkinghub.elsevier.com/retrieve/pii/S1078817421000493>
- [89] Wang T, Xiong Z, Zhou H, Luo W, Tang H, Liu J. Design, validation, and clinical practice of standardized imaging diagnostic report for COVID-19. *Zhong Nan Da Xue Xue Bao Yi Xue Ban* 2020;45:229-35. Doi: 10.11817/j.issn.1672-7347.2020.200152
- [90] Xiong Z, Fu L, Zhou H, Liu J, Wang A, Huang Y. Construction and evaluation of a novel diagnosis pathway for 2019-coronavirus disease. *Zhonghua Yi Xue za Zhi* 2020;100:1223-9. Doi: 10.3760/cma.j.cn112137-20200228-00499
- [91] Infantado MA, Villanueva CA, Bayona HH. Should CT scan be used to diagnose COVID-19 infection among suspected patients? Evidence Summary [Internet]. *Psmid.org*. 2021 [cited 2021 Dec 9]. Available from: <https://www.psmid.org/chest-ct-scan-evidence-summary/>



## Philippine COVID-19 Living Clinical Practice Guidelines

- [92] Liu TY, Rai A, Ditkofsky N, Deva DP, Dowdell TR, Ackery AD, et al. Cost benefit analysis of portable chest radiography through glass: Initial experience at a tertiary care centre during COVID-19 pandemic. *J Med Imaging Radiat Sci.* 2021;52(2):186–90. doi: 10.1016/j.jmir.2021.03.036
- [93] World Health Organization. Use of chest imaging in COVID-19: A rapid advance guide [Internet]. 2020 Jun. Available from: [https://apps.who.int/iris/bitstream/handle/10665/332336/WHO-2019-nCoV-Clinical-Radiology\\_imaging-2020.1-eng.pdf](https://apps.who.int/iris/bitstream/handle/10665/332336/WHO-2019-nCoV-Clinical-Radiology_imaging-2020.1-eng.pdf)
- [94] Philippine Pediatric Society & Pediatric Infectious Disease Society of the Philippines . Interim Guidelines on the Screening, Assessment and Clinical Management of Pediatric Patients with Suspected or Confirmed Coronavirus Disease 2019 (COVID-19), 06 February 2021. Available from <http://www.pidsphil.org/home/wp-content/uploads/2021/02/1613518307591635.pdf>.
- [95] Centers for Disease Control. (2021). Laboratory and Radiographic Findings: Testing for Infection. 2021. Available at <https://www.cdc.gov/coronavirus/2019-ncov/hcp/clinical-guidance-management-patients.html>.
- [96] ACR Recommendations for the use of chest radiography and computed tomography (CT) for suspected COVID-19 infection. American College of Radiology, 2020. Available at <https://www.acr.org/Advocacy-and-Economics/ACR-Position-Statements/Recommendations-for-Chest-Radiography-and-CT-for-Suspected-COVID19-Infection>.
- [97] Decision Support System Algorithm for COVID-19 Diagnosis [Internet]. Clinicaltrials.gov. [cited 2021 Dec 9]. Available from: <https://clinicaltrials.gov/ct2/show/NCT04479319?term=chest+CT+scan&recrs=abdef&type=Obsr&cond=COVID-19&outc=diagnosis+OR+sensitivity+or+specificity&draw=2&rank=1>
- [98] Prediction of Clinical Course in COVID19 Patients - Full Text View - ClinicalTrials.Gov [Internet]. Clinicaltrials.gov. [cited 2021 Dec 9]. Available from: <https://clinicaltrials.gov/ct2/show/NCT04377685?term=chest+CT+scan&recrs=abdef&type=Obsr&cond=COVID-19&outc=diagnosis+OR+sensitivity+or+specificity&draw=2&rank=2>
- [99] Multicentric Retrospective Observational Study of Thoracic Scanner Performance in COVID Screening [Internet]. Clinicaltrials.gov. [cited 2021 Dec 9]. Available from: <https://clinicaltrials.gov/ct2/show/NCT04339686?term=chest+CT+scan&recrs=abdef&type=Obsr&cond=COVID-19&intr=CT+scan&outc=diagnosis+OR+sensitivity+or+specificity&draw=2&rank=2>
- [100] Risk Stratification With Chest CT to Rule-out Suspected SARS-CoV-2 Infections - Full Text View - ClinicalTrials.Gov [Internet]. Clinicaltrials.gov. [cited 2021 Dec 9]. Available from: <https://clinicaltrials.gov/ct2/show/NCT04357938?term=chest+CT+scan&recrs=abdef&type=Obsr&cond=COVID-19&intr=CT+scan&outc=diagnosis+OR+sensitivity+or+specificity&draw=2&rank=5>
- [101] Accuracy of Lung Ultrasound in the Diagnosis of covid19 Pneumonia - Full Text View - ClinicalTrials.Gov [Internet]. Clinicaltrials.gov. [cited 2021 Dec 9]. Available from: <https://clinicaltrials.gov/ct2/show/NCT04370275?term=lung+ultrasound&recrs=abdef&type=Obsr&cond=COVID-19&intr=lung+ultrasound&outc=diagnosis+OR+sensitivity+or+specificity&draw=2&rank=2>
- [102] International Lung UltraSound Analysis (ILUSA) Study - Full Text View - ClinicalTrials.Gov [Internet]. Clinicaltrials.gov. [cited 2021 Dec 9]. Available from: <https://clinicaltrials.gov/ct2/show/NCT04353141?term=lung+ultrasound&recrs=abdef&type=Obsr&cond=COVID-19&intr=lung+ultrasound&outc=diagnosis+OR+sensitivity+or+specificity&draw=2&rank=3>
- [103] The Use of Focused Lung Ultrasound in Patients Suspected of COVID-19 [Internet]. Clinicaltrials.gov. [cited 2021 Dec 9]. Available from: <https://clinicaltrials.gov/ct2/show/NCT04327674?term=chest+CT+scan&recrs=abcdef&type=Obsr&cond=COVID-19&hlth=Y&draw=2&rank=5>
- [104] Evaluation of a COVID-19 Pneumonia CXR AI Detection Algorithm [Internet]. Clinicaltrials.gov. [cited 2021 Dec 9]. Available from: <https://clinicaltrials.gov/ct2/show/NCT04561024?term=chest+x-ray&recrs=abdef&type=Obsr&cond=COVID-19&intr=chest+x-ray&outc=diagnosis+OR+sensitivity+or+specificity&draw=2&rank=2>



# Philippine COVID-19 Living Clinical Practice Guidelines

## Appendix 1. Evidence to Decision

Table 1. Summary of initial judgements prior to the panel discussion (N = 9)

FACTORS		JUDGEMENT				RESEARCH EVIDENCE/ADDITIONAL CONSIDERATIONS
<b>Problem</b>	No (1)	Yes (8)				In settings where RT-PCR is not available, thoracic imaging plays an important role in the diagnostic work-up of suspected symptomatic COVID-19 individuals.
<b>Benefits</b>	Large (2)	Moderate (3)	Small (2)	Uncertain (2)		
<b>Harms</b>	Large	Moderate (2)	Small (5)	Uncertain (2)		For chest x-ray, using the pooled sensitivity of 72%, the false negative rate is at 28%. For lung ultrasound, using the pooled sensitivity of 93%, the false negative rate is at 7%. For chest CT scan, using the pooled sensitivity of 85%, the false negative rate is at 15%.
<b>Balance of Benefits and Harms</b>	Favors the use of thoracic imaging (5)	Probably favors the use of thoracic imaging (2)	Does not favor the use of thoracic imaging (2)			
<b>Certainty of Evidence</b>	High (1)	Moderate	Low (2)	Very low (6)		For chest x-ray, certainty of evidence is Very low due to the very serious risk of bias, very high heterogeneity and imprecision. For lung ultrasound and chest CT scan, certainty of evidence is Very Low due to serious risk of bias, imprecision, and very high heterogeneity.
<b>Accuracy</b>	Very Accurate	Accurate (6)	Inaccurate (1)	Very Inaccurate	Uncertain	For chest x-ray, Sn 72% (62-81%) and Sp 76% (67-86%). Sensitivity was higher for studies that involved experienced readers, used standardized CXR scoring systems, and when testing was done late in the disease course. For lung ultrasound, Sn 93% (86-97%) and Sp 52% (33-71%). Sensitivity appeared higher when the test was used for symptomatic patients and when reader impression was used instead of a scoring system.





## Philippine COVID-19 Living Clinical Practice Guidelines

FACTORS		JUDGEMENT					RESEARCH EVIDENCE/ADDITIONAL CONSIDERATIONS
							For chest CT scan, Sn 85% (81-88%) and Sp 78% (71-84%). Accuracy estimates were higher under the following situations: (1) test is used among symptomatic patients, (2) contrast-enhanced CT scan machines, (3) results are interpreted by experienced readers, (4) standardized scoring systems are used.
<b>Values</b>	Important uncertainty or variability (3)	Possibly important uncertainty or variability (4)	Possibly NO important uncertainty or variability (2)	No important uncertainty or variability			
<b>Resources Required</b>	Uncertain	Large cost (3)	Moderate Cost (5)	Negligible cost or savings	Moderate savings (1)	Large savings	Chest x-ray cost range: Php 250 - Php 1450. Lung Ultrasound cost range: Php 360 - 2,500. Chest CT scan cost range: Php 2,600 - 12,700.
<b>Certainty of evidence of required resources</b>	No included studies (6)	Very low (2)	Low (1)	Moderate	High		
<b>Cost effectiveness</b>	No included studies (4)	Favors using thoracic imaging (2)	Does not favor either using thoracic imaging or the comparator (2)	Favors comparison (1)			No local data on economic evaluation of chest x-ray, lung ultrasound and chest CT scan specifically for COVID-19.
<b>Equity</b>	Uncertain (2)	Reduced (4)	Probably no impact	Increased (3)			
<b>Acceptability</b>	Uncertain (1)	No (1)	Yes (7)				
<b>Feasibility</b>	Uncertain (2)	No	Yes (7)				



# Philippine COVID-19 Living Clinical Practice Guidelines

## Appendix 2. Search Yield and Results

Search	Query	Results
#9	Search: (((((((covid-19) OR (novel coronavirus) OR (SARS-Cov-2) OR (NCOV) OR (covid-19[MeSH Terms])) OR (SARS-CoV-2[MeSH Terms])) OR (novel coronavirus[MeSH Terms])) OR (coronavirus infections[MeSH Terms])) AND ((((((RT PCR) OR (RT-PCR)) OR (reverse transcriptase polymerase chain reaction)) OR (RT-PCR[MeSH Terms])) OR (polymerase chain reaction, reverse transcriptase[MeSH Terms])) OR (pcr, reverse transcriptase[MeSH Terms])) AND (((((((chest computed tomography) OR (chest CT scan)) OR (chest CAT scan)) OR (chest computed tomography scan[MeSH Terms])) OR (chest CT scan[MeSH Terms])) OR (chest CAT scan[MeSH Terms])) OR (((((((chest ultrasound) OR (lung ultrasound) OR (thoracic ultrasound) OR (chest ultrasonography)) OR (lung ultrasonography)) OR (thoracic ultrasonography)) OR (chest ultrasound[MeSH Terms])) OR (lung ultrasound[MeSH Terms])) OR (thoracic ultrasound[MeSH Terms])) OR (((((((chest x-ray) OR (chest radiograph) OR (chest xray)) OR (chest xray[MeSH Terms])) OR (chest x-ray[MeSH Terms])) OR (chest radiograph[MeSH Terms])))) Filters: from 2020/1/1 - 2021/1/20 Sort by: Most Recent	973
#8	Search: (((((((covid-19) OR (novel coronavirus) OR (SARS-Cov-2) OR (NCOV) OR (covid-19[MeSH Terms])) OR (SARS-CoV-2[MeSH Terms])) OR (novel coronavirus[MeSH Terms])) OR (coronavirus infections[MeSH Terms])) AND ((((((RT PCR) OR (RT-PCR)) OR (reverse transcriptase polymerase chain reaction)) OR (RT-PCR[MeSH Terms])) OR (polymerase chain reaction, reverse transcriptase[MeSH Terms])) OR (pcr, reverse transcriptase[MeSH Terms])) AND (((((((chest computed tomography) OR (chest CT scan)) OR (chest CAT scan)) OR (chest computed tomography scan[MeSH Terms])) OR (chest CT scan[MeSH Terms])) OR (chest CAT scan[MeSH Terms])) OR (((((((chest ultrasound) OR (lung ultrasound) OR (thoracic ultrasound) OR (chest ultrasonography)) OR (lung ultrasonography)) OR (thoracic ultrasonography)) OR (chest ultrasound[MeSH Terms])) OR (lung ultrasound[MeSH Terms])) OR (thoracic ultrasound[MeSH Terms])) OR (((((((chest x-ray) OR (chest radiograph) OR (chest xray)) OR (chest xray[MeSH Terms])) OR (chest x-ray[MeSH Terms])) OR (chest radiograph[MeSH Terms])))) Sort by: Most Recent	1,006
#7	Search: ((((((RT PCR) OR (RT-PCR)) OR (reverse transcriptase polymerase chain reaction)) OR (RT-PCR[MeSH Terms])) OR (polymerase chain reaction, reverse transcriptase[MeSH Terms])) OR (pcr, reverse transcriptase[MeSH Terms])) AND (((((((chest computed tomography) OR (chest CT scan)) OR (chest CAT scan)) OR (chest computed tomography scan[MeSH Terms])) OR (chest CT scan[MeSH Terms])) OR (chest CAT scan[MeSH Terms])) OR (((((((chest ultrasound) OR (lung ultrasound) OR (thoracic ultrasound) OR (chest ultrasonography)) OR (lung ultrasonography)) OR (thoracic ultrasonography)) OR (chest ultrasound[MeSH Terms])) OR (lung ultrasound[MeSH Terms])) OR (thoracic ultrasound[MeSH Terms])) OR (((((((chest x-ray) OR (chest radiograph) OR (chest xray)) OR (chest xray[MeSH Terms])) OR (chest x-ray[MeSH Terms])) OR (chest radiograph[MeSH Terms])))) Sort by: Most Recent	1,353
#6	Search: ((((((RT PCR) OR (RT-PCR)) OR (reverse transcriptase polymerase chain reaction)) OR (RT-PCR[MeSH Terms])) OR (polymerase chain reaction, reverse transcriptase[MeSH Terms])) OR (pcr, reverse transcriptase[MeSH Terms])) Sort by: Most Recent	276,677
#5	Search: (((((((chest computed tomography) OR (chest CT scan)) OR (chest CAT scan)) OR (chest computed tomography scan[MeSH Terms])) OR (chest CT scan[MeSH Terms])) OR (chest CAT scan[MeSH Terms])) OR (((((((chest ultrasound) OR (lung ultrasound) OR (thoracic ultrasound) OR (chest ultrasonography)) OR (lung ultrasonography)) OR (thoracic ultrasonography)) OR (chest ultrasound[MeSH Terms])) OR (lung ultrasound[MeSH Terms])) OR (thoracic ultrasound[MeSH Terms])) OR (((((((chest x-ray) OR (chest radiograph) OR (chest xray)) OR (chest xray[MeSH Terms])) OR (chest x-ray[MeSH Terms])) OR (chest radiograph[MeSH Terms])))) Sort by: Most Recent	255,939
#4	Search: (((((((chest computed tomography) OR (chest CT scan)) OR (chest CAT scan)) OR (chest computed tomography scan[MeSH Terms])) OR (chest CT scan[MeSH Terms])) OR (chest CAT scan[MeSH Terms])) Sort by: Most Recent	56,031
#3	Search: (((((((chest ultrasound) OR (lung ultrasound) OR (thoracic ultrasound) OR (chest ultrasonography)) OR (lung ultrasonography)) OR (thoracic ultrasonography)) OR (chest ultrasound[MeSH Terms])) OR (lung ultrasound[MeSH Terms])) OR (thoracic ultrasound[MeSH Terms])) Sort by: Most Recent	210,782
#2	Search: (((((((chest x-ray) OR (chest radiograph) OR (chest xray)) OR (chest xray[MeSH Terms])) OR (chest x-ray[MeSH Terms])) OR (chest radiograph[MeSH Terms])) Sort by: Most Recent	107,091
#1	Search: (((((((covid-19) OR (novel coronavirus) OR (SARS-Cov-2) OR (NCOV) OR (covid-19[MeSH Terms])) OR (SARS-CoV-2[MeSH Terms])) OR (novel coronavirus[MeSH Terms])) OR (coronavirus infections[MeSH Terms])) Sort by: Most Recent	210,386



## Philippine COVID-19 Living Clinical Practice Guidelines

### Appendix 3. Characteristics of Included Studies

Study ID	Type of Study	Country	Population Description/Setting	Sample Size	Index Test	Index Test Criteria for Positivity	Reader Experience Description	Reference Standard	Number in Reference Section
Ai 2020	observational, retrospective, single center	China	adult suspected COVID-19 patients (unclear symptomatology)	1014	CT: not specified	Chest CT scan positive: GGO, consolidation, reticulation and/or thickened interlobular septa (nodules) and lesion distribution	Two radiologists with 12 and 3 years	RT PCR	[35]
Aslan 2020	observational, retrospective, single center	Turkey	adult suspected COVID-19 patients (all symptomatic) in emergency department	306	CT: low-dose CT	Radiological evidence of COVID-19 pneumonia, including presence of GGO, mixed GGO (GGO and consolidation), consolidation, distribution and number of lobes and segment affected by GGO and/or consolidation, etc	two experienced radiologist	RT PCR	[36]
Bagci 2021	observational, retrospective, single center	Turkey	electronic archive records of children aged 0-18 yrs old suspected of COVID-19 (symptomatics and possibly asymptomatic) who underwent CT scan	89	CT: not specified	presence of pulmonary lesions (GGO, consolidation, halo sign, nodules, vascular fullness, fibrosis), lesion type, pulmonary involvement areas, and maximum lobe involvement percentage	single experienced pediatric radiologist	RT PCR	[37]
Bar 2020	observational, prospective, single center	France	adults (unclear symptomatology) admitted to the emergency room whose lungs were imaged with ultrasound for suspected COVID-19 infection and who had a SARS-CoV-2 RT-PCR test	100	LUS: point-of-care US, BLUE protocol, curved probe	unclear	LUS done by emergency physician but experience not reported	RT PCR	[27]
Barbosa 2020	observational, retrospective, single center	Brazil	adult suspected COVID-19 patients (all symptomatic)	91	CT: not specified	Radiology Society of North America (RSNA)	two experienced radiologist	RT PCR	[38]
Bellini 2020	observational, retrospective, single center	Italy	suspected of COVID-19 (all symptomatic) presenting at the ER	572	CT: non-contrast enhanced CT	COVID-19 Reporting and Data System (CO-RADS)	radiologists and radiographers	RT PCR	[39]
Berkel 2021	observational, retrospective, single center	Belgium	CT scan records of suspected COVID-19 (unclear symptomatology)	200	CT: mixed types	mixed: CO-RADS + CTIS	a senior thoracic radiologist with	RT PCR	[40]



## Philippine COVID-19 Living Clinical Practice Guidelines

Study ID	Type of Study	Country	Population Description/Setting	Sample Size	Index Test	Index Test Criteria for Positivity	Reader Experience Description	Reference Standard	Number in Reference Section
			who underwent CT scan and RT PCR in a hospital				21-year experience and a resident radiologist with one-year experience with discrepant cases were evaluated by a senior thoracic radiologist with 10-year experience		
Besutti 2020	observational, cross-sectional, single center	Italy	suspected of COVID-19 (all symptomatic) presenting at the ER	696	CT: non-contrast enhanced CT	a structured report about probability of COVID19 pneumonia (radiologist impression – highly suggestive, suggestive, not suggestive)	radiologist, no details on experience	RT PCR	[41]
Bitar 2021	observational, prospective, single center	Kuwait	adults with suspected COVID-19 infection (symptomatic only) who were transferred to ICU	77	LUS: point-of-care US, 12-zone scan, curvilinear	4 LUS findings of COVID pneumonia: Bilateral B-lines in separate forms and bilateral patchy shining white lung areas in multiform clusters, where all these signs are represented and sharply alternated to “spared areas”; Bilateral diffuse irregularities of the pleural line; Absence of significant pleural effusion; Presence of multiple subpleural consolidations of various sizes	Level 4 operator in critical care clinical ultrasound (entrusted to act unsupervised)	RT PCR	[28]
Borakati 2020	observational, retrospective, single center	UK	electronic records of suspected of COVID-19 (symptomatic or asymptomatic) presenting at the ER who had RT PCR, CXR and Ct scan done	CXR: 860 CT: 302	CXR: Not specified  CT: different types	CXR: British Society of Thoracic Imaging (BSTI) reporting criteria  CT: British Society of Thoracic Imaging (BSTI) reporting criteria	consultant radiologist	RT PCR	[9]
Cartocci 2020	observational, retrospective, single center	Italy	adults suspected of COVID-19 (all symptomatic) presenting at the ER	314	CT: not specified	classification system based another study (typical CT pattern, possible CT pattern,	radiologist with 8 and 16 yrs of experience	RT PCR	[42]



## Philippine COVID-19 Living Clinical Practice Guidelines

Study ID	Type of Study	Country	Population Description/Setting	Sample Size	Index Test	Index Test Criteria for Positivity	Reader Experience Description	Reference Standard	Number in Reference Section
						inconsistent CT pattern, negative for pneumonia)			
Caruso 2020	observational, prospective, single center	Italy	adults suspected of COVID-19 (all symptomatic) presenting at the ER	158	CT: non-contrast enhanced CT	pneumonia (GGO, multilobar, bilateral distribution, oosterior involvement)	radiologist with 5 and 25 years of thoracic imaging experience	RT PCR	[43]
Choudhury 2020	observational, prospective, single center	India	suspected of COVID-19 (all symptomatic) presenting in a respiratory unit	97	CXR: Not specified	previously unvalidated Likert score (scores 1 to 5) based on radiographic features thought to be related to COVID-19	radiologist: experience not specified	RT PCR	[10]
Cozzi 2020	observational, retrospective, single center	Italy	all patients presenting to the emergency department for suspected SARS-CoV-2 infection (symptomatic or asymptomatic) who underwent both a nasopharyngeal swab for RT-PCR and an anteroposterior bedside CXR within 12 h from admission.	535	CXR: portable/bedside	The presence of interstitial infiltrates with predominantly bilateral and basal distribution	2 groups of radiologist (1 group with 10 or more years of experience & another group with less than 10 years of experience)	RT PCR	[11]
De Smet 2020	observational, prospective, single center	Belgium	admitted to the hospital with clinical suspicion of COVID-19 pneumonia (symptomatic individuals) and individuals without COVID-19 symptoms but admitted for other medical emergencies, scheduled surgery, or medical procedures and psychiatric or geriatric care ("asymptomatic")	859	CT: non-contrast enhanced CT	COVID-19 Reporting and Data System (CO-RADS)	cardiothoracic radiologist with 9 and 24 yrs of experience	RT PCR	[44]
Debray 2020	observational, retrospective, single center	France	adults suspected of COVID-19 (unclear symptomatology)	241	CT: non-contrast enhanced CT	French Society of Radiology criteria	radiologists and emergency physicians	RT PCR	[45]



## Philippine COVID-19 Living Clinical Practice Guidelines

Study ID	Type of Study	Country	Population Description/Setting	Sample Size	Index Test	Index Test Criteria for Positivity	Reader Experience Description	Reference Standard	Number in Reference Section
Deng 2020	observational, retrospective, single center	China	suspected of COVID-19 (all symptomatic)	587	CT: high-resolution CT	Any of the following: GGO; Thickened blood vessels; Thickened bronchial shadows passing through; With or without localized lobular septal grid thickening; Single or multiple real shadows	radiologist with 5 and 20 yrs of experience	RT PCR	[46]
Dini 2020	observational, prospective, multi center	Italy	more than 70 yrs old suspected of COVID-19 in nursing homes (symptomatic and asymptomatic who are contacts of previously positive COVID)	150	LUS: point-of-care US, not specified scan protocol, curvilinear probe	4-level scoring system	Reader not specified	RT PCR	[29]
Dofferhoff 2020	observational, prospective, single center	Netherlands	suspected of COVID-19 (all symptomatic) presenting at the ER	312	CT: low-dose CT	COVID-19 Reporting and Data System (CO-RADS)	radiologist, no details on experience	RT PCR	[47]
Du 2021	observational, retrospective, multi center	Hong Kong	more than 16 years old with clinical suspicion of COVID-19 infection (all symptomatic) presenting to the accident and emergency department in different hospitals in Hong Kong	605	CXR: Not specified	pre-defined set of CXR findings were used based on local experience and emerging literature to define "typical" radiographic features of COVID-19	four board certified radiologist with subspecialty training in thoracic radiology (experience: 2 to 15 years)	RT PCR	[12]
Ducray 2020	observational, retrospective, multi center	France	adults suspected of COVID-19 (symptomatic or asymptomatic) presenting at the ER	694	CT: contrast-enhanced CT	classification system: surely COVID+, possible COVID+, COVID-	senior radiologist, no details on experience	RT PCR	[48]
Falaschi 2020	observational, retrospective, single center	Italy	adults suspected of COVID-19 (all symptomatic) presenting at the ER during peak of Italian pandemic	773	CT: non-contrast enhanced CT	Radiology Society of North America (RSNA)	Two radiologists with more than 10 years of thoracic imaging experience	RT PCR	[49]
Fonsi 2020	observational, prospective, single center	Italy	adults suspected (all symptomatic) of COVID-19 at ER	63	LUS: point-of-care US, 12-zone	LUS: unclear CT features: GGOs; consolidation; a mixed GGO and consolidation	LUS: 2 examiners who were	RT PCR	[30]



## Philippine COVID-19 Living Clinical Practice Guidelines

Study ID	Type of Study	Country	Population Description/Setting	Sample Size	Index Test	Index Test Criteria for Positivity	Reader Experience Description	Reference Standard	Number in Reference Section
					scan, curvilinear  CT: non-contrast enhanced CT	pattern; single or multiple solid nodules surrounded by GGOs; a focal or multifocal distribution; GGO and consolidation location; multilobe involvement; a bilateral distribution; interlobular septal thickening; an air bronchogram; the presence of cavitation; bronchial wall thickening; bronchiectasis; mediastinal lymph node enlargement; pleural effusion; and pericardial effusion	experienced in echography  CT: 2 radiologists, who were experienced in chest imaging, studied all chest CT images.		
Fujioka 2020	observational, retrospective, single center	Japan	adults suspected of COVID-19 (all symptomatic)	154	CT: not specified	COVID-19 Reporting and Data System (CO-RADS)	radiologist resident and board-certified radiologist	RT PCR	[50]
Gezer 2020	observational, retrospective, single center	Turkey	adults suspected of COVID-19 (all symptomatic)	222	CT: non-contrast enhanced CT	unclear definition	radiologist with 14 yrs of experience	RT PCR	[51]
Giannitto 2020	observational, retrospective, single center	Italy	adults suspected of COVID-19 (all symptomatic) presenting at the ER	68	CT: non-contrast enhanced CT	classification system: surely COVID+, possible COVID+, COVID-	Two radiologists with five and fifteen years of experience	RT PCR	[52]
Gibbons 2021	observational, prospective, single center	USA	more than 18 years old presenting at the ER with signs and symptoms of COVID-19	101	CXR: portable/bed side  LUS: point-of-care US, 8-zone scan, Butterfly iQ	CXR: presence of infiltrate or pneumonia  LUS findings consistent with viral/atypical pneumonia: irregular pleural line, B-lines, consolidation, and pleural effusion; the presence of three or more B-lines was considered positive; the presence of a single confluent B-line encompassing a third or more of the visualized distal intercostal space was considered positive; presence of one of the aforementioned sonographic findings defined a positive zone; presence of two or more positive zones was defined as diagnostic	CXR: Not specified  LUS: Experienced-ultrasound-fellowship-trained emergency medical doctors; Inexperienced - postgraduate year (PGY)1-3 emergency medicine resident or emergency medicine attending with American College of Emergency Physician (ACEP) credentials for point-of-care ultrasound, the	RT PCR	[13]



## Philippine COVID-19 Living Clinical Practice Guidelines

Study ID	Type of Study	Country	Population Description/Setting	Sample Size	Index Test	Index Test Criteria for Positivity	Reader Experience Description	Reference Standard	Number in Reference Section
							reviewed a 2 min video on LUS for viral pneumonia prior to start of study		
Gichoya 2021	observational, retrospective, single center, case-control	USA	retrieved and reviewed the chest radiographs taken at the time of ER presentation of known COVID PCR positive and COVID PCR negative patients	1638	CXR: different types	instructed to label images with the single best label from the following six choices: Normal, COVID-19, Other Infectious, Other Noninfectious, Nondiagnostic Image, or Endotracheal Tube Present.	radiologist with varying specialties and experiences	RT PCR	[14]
Gietema 2020	observational, prospective, single center	Netherlands	adults suspected of COVID-19 (all symptomatic) presenting at the ER	193	CT: non-contrast enhanced CT	standardized imaging reporting system (typical for COVID-19, equivocal, non COVID-19)	initial reading by resident but final reading done by experienced chest radiologist with 12 years of experience	RT PCR	[53]
Grando 2020	observational, cross-sectional, single center	Brazil	Patients with suspected COVID-19 pneumonia (all symptomatics) submitted to RT-PCR test and chest computed tomography	159	CT: high-resolution	Radiology Society of North America (RSNA)	2 radiologist (1 and 10 yrs of experience) but discordant reports evaluated by another radiologist with 12 yrs experience	RT PCR	[54]
Guillo 2020	observational, retrospective, single center	France	adults suspected of COVID-19 (all symptomatic) presenting at the ER	214	CT: non-contrast enhanced CT	structured report about probability of COVID-19 pneumonia based on the presence of GGOs, with or without crazy paving pattern, isolated or admixed with perilobular or linear consolidation, their peripheral or central distribution	initial reading by radiology resident then approved by a senior radiologist. Secondly independently reviewed by an experienced chest radiologist with 20 years of experience (blinded to 1st review)	RT PCR	[55]





## Philippine COVID-19 Living Clinical Practice Guidelines

Study ID	Type of Study	Country	Population Description/Setting	Sample Size	Index Test	Index Test Criteria for Positivity	Reader Experience Description	Reference Standard	Number in Reference Section
Haak 2020	observational, prospective, single center	Netherlands	more than 16 years old suspected of COVID (all symptomatic) presenting to the ED	93	LUS: point-of-care US, 12-zone scan, curved	POCUS of the lungs scoring system for pulmonary manifestation of COVID-19	Emergency Medicine resident with 2.5 years of POCUS experience did the ultrasound but the reading was done by an emergency physician and expert sonographer	RT PCR	[31]
He 2020	observational, retrospective, single center	China	suspected COVID-19 patients (unclear symptomatology)	82	CT: non-contrast enhanced CT	GGO with or without consolidation, crazy paving pattern, peripheral and diffuse distribution and bilateral/multilobular involvement	Two experienced general radiologists with 17 and 14 years of experience	RT PCR	[56]
Hermans 2020	observational, prospective, single center	Netherlands	adults suspected COVID-19 patients (symptomatic and asymptomatic) presenting at the ER	319	CT: not specified	COVID-19 Reporting and Data System (CO-RADS)	Twenty board-certified radiologists	RT PCR	[57]
Hernigu 2020	observational, retrospective, single center	Belgium	adults suspected COVID-19 patients (symptomatic and asymptomatic) presenting at the ER with diagnosis of trauma that underwent chest CT	47	CT: low-dose CT	unclear definition	read by two radiologist (one with 30 years of experience)	RT PCR	[58]
Herpe 2020	observational, prospective, single center	France	suspected COVID-19 patients (all symptomatic)	4824	CT: not specified	bilateral GGO with peripheral distribution, bilateral paving appearance with intralobular thickening, reverse halo sign, or other signs compatible with organizing pneumonia	experienced radiologist with at least 5 yrs of experience	RT PCR	[59]
Hwang 2020	observational, retrospective, single center	Korea	People who visited a tertiary hospital with suspected COVID-19 (symptomatic or asymptomatic) who underwent chest x-ray	332	CXR: portable/bed side	abnormality suggesting pneumonia	thoracic radiologist with 9 years of experience	RT PCR	[15]



## Philippine COVID-19 Living Clinical Practice Guidelines

Study ID	Type of Study	Country	Population Description/Setting	Sample Size	Index Test	Index Test Criteria for Positivity	Reader Experience Description	Reference Standard	Number in Reference Section
Hwang 2021	observational, retrospective, multi center	Korea	Patients with and without COVID-19 confirmed with RT-PCR that underwent CXR and chest CT in four different institutions	172	CXR: Not specified	Five point scale score: a) score 1, definitely absent; b) score 2, probably absent; c) score 3, equivocal; d) score 4, probably present; and e) score 5, definitely present.	5 thoracic radiologists with range of 5 - 29 years of experience & non-radiologist physicians	RT PCR	[16]
Ippolito 2020	observational, retrospective, single center	Italy	patients suspected of COVID-19 (all symptomatic) presenting at the ER who underwent CXR & PCR	518	CXR: portable/bed side	presence of reticulations, alveolar opacities or both	single radiologist with more than 15 years of experience	RT PCR	[17]
Kalin 2021	observational, retrospective, single center	Turkey	pediatric patients (0–18 age) who were referred to the radiology department with suspicion of COVID-19 (unclear symptomatology) pneumonia and underwent low-dose chest CT scan	148	CT: low-dose CT	CT findings consistent of pneumonia; details not specified	pediatric radiologist with 15 yrs of experience	RT PCR	[60]
Kavak 2021	observational, retrospective, single center	Turkey	patients with history of contact or symptoms of COVID-19 presenting at the ER that underwent chest CT examination	903	CT: non-contrast enhanced CT	Radiology Society of North America (RSNA) & British Society of Thoracic Imaging (BSTI) reporting criteria	two radiologists with a 14 and 15 years of experience	RT PCR	[61]
Khan 2021	observational, prospective, single center	Pakistan	confirmed and suspected COVID-19 (all symptomatics) patients admitted in the ward and ICU that was referred for chest X-rays and computed tomography (CT) scans	CXR: 533; CT: 97	CXR: portable/bed side  CT: mixed types	CXR: Radiographic Assessment of Lung Edema (RALE) criteria  CT: chest CT scan severity score (CTSS)	2 junior radiologist and 2 senior radiologist with 10 years of experience	RT PCR	[18]
Kiziloglu 2021	observational, retrospective, single center	Turkey	more than 18 years old suspected of COVID-19 (all symptomatic) presenting at the ER	173	CT: not specified	thorax CT images were classified as normal, non- COVID lung findings, compatible with low probability COVID- 19, intermediate probability COVID- 19 and high probability- definite COVID- 19 as defined in other studies	Two radiologists experienced in the field of thorax CT	RT PCR	[62]



## Philippine COVID-19 Living Clinical Practice Guidelines

Study ID	Type of Study	Country	Population Description/Setting	Sample Size	Index Test	Index Test Criteria for Positivity	Reader Experience Description	Reference Standard	Number in Reference Section
Korevaar 2020	observational, retrospective, single center	Netherlands	adults suspected of COVID-19 (all symptomatic) presenting at the ER	239	CT: low-dose CT	COVID-19 Reporting and Data System (CO-RADS)	radiologist, no details on experience	RT PCR	[63]
Krdzalic 2020	observational, retrospective, single center	Netherlands	adults suspected of COVID-19 (all symptomatic)	56	CT: non-contrast enhanced CT	COVID-19 Reporting and Data System (CO-RADS)	chest radiologist with 5 years of experience in chest CT interpretation	RT PCR	[64]
Kuzan 2020	observational, retrospective, single center	Turkey	adults suspected of COVID-19 (all symptomatic) presenting at the ER	120	CT: non-contrast enhanced CT	British Society of Thoracic Imaging (BSTI) reporting criteria	radiologist, no details on experience	RT PCR	[65]
Li 2020	observational, retrospective, multi center	China	adults suspected of COVID-19 (all symptomatic)	92	CT: not specified	specific scoring criteria based on literature findings	two radiologists with 3 and 10 years of experience in chest imaging	RT PCR	[66]
Lieveld 2020	observational, prospective, multi center	Netherlands	patients 18 years and older who were referred to the ED for internal medicine with suspected COVID-19 (all symptomatic)	186	LUS: point-of-care US, 12-zone scan, probe not specified  CT: not specified	LUS: three or more B-lines and/or consolidation in two or more zones unilaterally or in one or more zones bilaterally  CT: COVID-19 Reporting and Data System (CO-RADS)	LUS: performed or supervised by internists (mostly registrars) who were certified in point-of-care ultrasound and had performed at least 20 supervised LUS  CT: not specified	RT PCR	[32]
Luo L 2020	observational, retrospective, single center	China	adults suspected of COVID-19 (all symptomatic)	73	CT: not specified	scoring system was developed (with scores from -4 to +7)	two cardiothoracic radiologist with 15 and 25 years of experience	RT PCR	[67]
Luo N 2020	observational, retrospective, single center	China	adults suspected of COVID-19 (unclear symptomatology)	140	CT: not specified	unclear definition	cardiothoracic radiologist, no details on experience	RT PCR	[68]



## Philippine COVID-19 Living Clinical Practice Guidelines

Study ID	Type of Study	Country	Population Description/Setting	Sample Size	Index Test	Index Test Criteria for Positivity	Reader Experience Description	Reference Standard	Number in Reference Section
Majeed 2021	observational, prospective, single center	Pakistan	12 to 90 years old with symptoms of COVID that underwent CXR	105	CXR: portable/bed side	British Society of Thoracic Imaging (BSTI) reporting criteria	2 radiologist with 5 and 20 years of experience	RT PCR	[19]
Mei 2020	observational, retrospective, multi center	USA	suspected COVID-19 patients (symptomatic and asymptomatic)	905	CT: not specified	unclear definition	thoracic radiologist with 10 years of experience	RT PCR	[69]
Mirahma dizadeh 2021	observational, cross-sectional, single center	Iran	adult suspected COVID-19 patients (unclear symptomatology)	54	CT: not specified	presence of GGO & consolidation	not specified reader	RT PCR	[70]
MM Santos 2020	observational, retrospective, single center	Brazil	adults suspected of COVID-19 (all symptomatic) presenting at the ER	75	CT: not specified	Radiology Society of North America (RSNA)	two radiologists with 4 and 11 years of experience in chest imaging	RT PCR	[71]
Murphy 2020	observational, retrospective, single center	Netherlands	suspected of COVID-19 (all symptomatic)	454	CXR: Not specified	Classification system: normal, no finding (category 0); abnormal but no lung opacity consistent with pneumonia (category 1); lung opacity consistent with pneumonia (unlikely COVID-19) (category 2); lung opacity consistent with pneumonia (consistent with COVID-19) (category 3).	6 radiologist with 5 to 30 years of experience	RT PCR	[20]
Nair 2021	observational, retrospective, single center	Qatar	records of patients with clinical suspicion of COVID-19 (all symptomatic) in whom a CT chest examination was done	984	CT: not specified	COVID-19 Reporting and Data System (CO-RADS)	Fellowship trained chest radiologists with experience of reporting more than 200 COVID-19 CT chests; general radiologists without any subspecialty fellowships with reporting experience of 100 to 150 COVID-19 CT chest cases; and radiologist in training in PGY-5	RT PCR	[72]



## Philippine COVID-19 Living Clinical Practice Guidelines

Study ID	Type of Study	Country	Population Description/Setting	Sample Size	Index Test	Index Test Criteria for Positivity	Reader Experience Description	Reference Standard	Number in Reference Section
							with reporting experience of less than 100 COVID-19 CT chests		
Narinx 2020	observational, retrospective, single center	Belgium	suspected of COVID-19 (all symptomatic) presenting at the ER	90	LUS: point-of-care US, BLUE protocol, curved probe  CT: low-dose CT	LUS: positive if one or more BLUE points showed a positive B-line parameter  CT: suggestive for or inconsistent with COVID-19 infection based on the presence of clinical manifestations as presented by another study	LUS: emergency medical doctor all certified for lung ultrasound (US) and each having more than 5 years of US experience  CT: two cardiothoracic radiologists (with 8 and 7 years of cardiothoracic imaging experience)	RT PCR	[33]
Ohana 2020	observational, retrospective, single center	France	adult patients with a clinical suspicion of Covid-19 (all symptomatic) admitted to the Emergency Department during first wave in France	2194	CT: non-contrast enhanced CT	typical Covid-19 lesions: bilateral and predominantly peripheral and sub-pleural ground glass opacities and/or alveolar consolidations	Ten consultant radiologists (4 specialized in chest imaging) with 5–30 years of experience were	RT PCR	[73]
Ozer 2021	observational, retrospective, single center	Turkey	more than 18 yrs old suspected of COVID-19 (symptomatic or asymptomatic) admitted at the ER or outpatient clinics who underwent chest CT and RT PCR	1186	CT: non-contrast enhanced CT	Radiology Society of North America (RSNA)	radiologist with 5 yrs of experience, resident radiologist but overall decision is done with a thoracic radiologist with 8 yrs of experience	RT PCR	[74]
Ozkaraf akili 2021	observational, retrospective, single center	Turkey	more than 18 years old with symptoms of COVID-19 admitted at the ER who underwent chest CT and RT PCR	569	CT: non-contrast enhanced CT	CT findings consistent of pneumonia; details not specified	2 experienced radiologists	RT PCR	[75]



## Philippine COVID-19 Living Clinical Practice Guidelines

Study ID	Type of Study	Country	Population Description/Setting	Sample Size	Index Test	Index Test Criteria for Positivity	Reader Experience Description	Reference Standard	Number in Reference Section
Pare 2020	observational, retrospective, single center	USA	suspected of COVID-19 (all symptomatic) presenting at the ER who underwent PCR, LUS & CXR	43	CXR: Not specified  LUS: point-of-care US, 12 zone scan, mixed probes	CXR: report included infection in the differential, as defined by words such as opacity, consolidation, or airspace disease; negative if no abnormality was noted, an abnormality was noted but attributed to a non-infectious etiology, or was inconclusive for infectious process; LUS: presence of B-lines	CXR: Not specified; only mentioned that official xray report was used: LUS: expert emergency physicians with clinical ultrasound fellowship training	RT PCR	[21]
Patel 2020	observational, retrospective, single center	USA	suspected COVID-19 patients (all symptomatic) presenting in the ER	317	CT: high-resolution CT	Scoring system: consistent with multifocal pneumonia (category 1); indeterminate for multifocal pneumonia (category 2); not consistent with multifocal pneumonia (category 3)	3 radiologist with more than 20 years of experience	RT PCR	[76]
Peng 2020	observational, retrospective, single center	China	pediatric patients suspected of COVID-19 (symptomatic and asymptomatic)	72	CT: not specified	presence of GGO, consolidations, with surrounding halo sign, nodules, residual fibre strip, lymphadenopathy	Two experienced pediatric radiologist	RT PCR	[77]
Peyrony 2020	observational, prospective, single center	France	adult patients with suspected COVID-19 (all symptomatic) who were tested for SARS-CoV-2 in the emergency department	CXR: 129; LUS: 84	CXR: Not specified  LUS: point-of-care US, scan protocol & probe not specified	CXR: linclear; LUS: presence of B-lines	CXR: Not specified; LUS: emergency physician but experience not reported	RT PCR	[22]
Prokop 2020	observational, retrospective, single center	Netherlands	suspected COVID-19 patients (all symptomatic) presenting in the ER	105	CT: not specified	COVID-19 Reporting and Data System (CO-RADS)	radiologists with varying years of experience	RT PCR	[78]
Ravikant h 2021	observational, cross-sectional, single center	India	adults with clinical suspicion of COVID-19 (all symptomatic) referred to a tertiary care hospital	348	CT: non-contrast enhanced CT	assessed as suspicious or not suspicious of COVID; details not specified	initial judgment by senior resident but final reading by experienced chest radiologist	RT PCR	[79]



## Philippine COVID-19 Living Clinical Practice Guidelines

Study ID	Type of Study	Country	Population Description/Setting	Sample Size	Index Test	Index Test Criteria for Positivity	Reader Experience Description	Reference Standard	Number in Reference Section
Revel 2021	observational, retrospective, multi center	France	CT scans of individuals more than 18 years old suspected of COVID-19 (all symptomatic) presenting at the ER of 20 hospitals during first wave of SARS-CoV-2 in France	10735	CT: high-resolution CT	French Society of Radiology criteria	junior radiologist (0.6 to 3 yrs of experience) and senior radiologist (5 to 34 years of experience)	RT PCR	[80]
Saeed 2021	observational, retrospective, single center	UAE	suspected to have COVID-19 infection (symptomatics and asymptomatics) presenting at the ER	93	CT: high-resolution CT	Radiology Society of North America (RSNA)	Two radiologists with more than 8 years of experience	RT PCR	[81]
Schiaffino 2020	observational, retrospective, single center	Italy	suspected of COVID-19 (unclear symptomatology) presenting at the ER	535	CXR: portable/bed side	positive or negative according to original radiologic reports	radiologist experience not specified	RT PCR	[23]
Schulze-Hagen 2020	observational, prospective, single center	Germany	adults suspected of COVID-19 (all symptomatic) presenting at the ER	191	CT: low-dose CT	COVID-19 Reporting and Data System (CO-RADS)	radiologist, no details on experience	RT PCR	[82]
Shirota 2021	observational, retrospective, multi center	Japan	suspected to have COVID-19 infection (symptomatics and asymptomatic close contact) who underwent chest CT and RT PCR in the hospital and outpatient setting	66	CT: not specified	Radiology Society of North America (RSNA)	two board-certified diagnostic radiologists with 6 and 11 years of experience with chest CT	RT PCR	[83]
Simsek Yurt 2021	observational, retrospective, single center	Turkey	patients admitted to the Emergency Department with the prediagnosis of COVID-19 (symptomatic and asymptomatic)	3334	CT: not specified	occurrences of peripheral, bilateral, ground glass opacity, multifocal round ground glass opacity (they can be accompanied by other findings of organised pneumonia such as paving stone appearance, consolidation, reverse-halo)	not specified reader	RT PCR	[84]
Song 2020	observational, retrospective, single center	China	adults suspected of COVID-19 (all symptomatic)	211	CT: not specified	diagnosis of viral pneumonia accordg to: multiple bilateral, ill-defined GGOs or mixed consolidation with diffuse peripheral distribution or bilateral pulmonary consolidation	2 radiologists with 8 and 4 years of experience	RT PCR	[85]



## Philippine COVID-19 Living Clinical Practice Guidelines

Study ID	Type of Study	Country	Population Description/Setting	Sample Size	Index Test	Index Test Criteria for Positivity	Reader Experience Description	Reference Standard	Number in Reference Section
Stephane 2020	observational, retrospective, multi center, case-control	USA	adults who had undergone both at least one nucleic acid amplification-based COVID-19 detection test and at least one chest radiography or CT examination that was performed within a week of testing	CXR: 500; CT: 169	CXR: Not specified  CT: Not specified	CXR: assign a severity score for the chest radiography findings: normal, mild, moderate, or severe based on predominant pattern on chest radiographs electing from interstitial opacities, interstitial and airspace (IA) opacities, atelectasis, diffuse airspace (DA) opacities, lobar consolidation, or peripheral opacities; also assigned COVID-19 likelihood score between 1 and 5 (1 being "very unlikely," 3 being "intermediate likelihood," and 5 being "highly likely")  CT: CTSS + COVID-19 Likelihood score	varying reader experience in different institutions (4 to 29 years of experience)	RT PCR	[24]
Stevens 2020	observational, retrospective, single center	UK	adults suspected of COVID-19 (all symptomatic) attending the Emergency Department	320	CXR: Not specified	British Society of Thoracic Imaging (BSTI) reporting criteria	consultant practitioner radiologist and advanced practitioner radiologist	RT PCR	[25]
Stuewe 2020	observational, retrospective, single center	Germany	adults suspected of COVID-19 (all symptomatic)	105	CT: low-dose CT	unclear definition	radiologist	RT PCR	[86]
Thomas 2021	observational, retrospective, multi center	France	patients suspected of COVID-19 pneumonia who underwent RT-PCR and chest CT	487	CT: not specified	positive for COVID-19: in cases of typical imaging patterns, including bilateral, subpleural and peripheral ground-glass opacities (GGOs), crazy paving appearance (GGOs and inter-/intra-lobular septal thickening), and bronchovascular thickening.	experimented radiologist senior (mean 10 years of experience $\pm$ 5) and one resident (mean 3 years of experience $\pm$ 2) using standardized CT reports	RT PCR	[87]
Tung-Chen 2021	observational, prospective, multi center	Spain	more than 18 years old presenting at the ER with clinical suspicion of COVID-19 (all symptomatic) requiring CXR	88	CXR: Not specified  LUS: point-of-care US, 12 zone scan, mixed probes	CXR: GGO, interstitial pattern  LUS: bilateral pattern of B-lines, isolated or confluent, irregular pleural lines, and/or sub- pleural consolidations	CXR: Two radiologist trainees with 2-4 years of experience under the supervision of a senior radiologist with more than 10 years of experience  LUS: UTZ fellowship trained	RT PCR	[26]





## Philippine COVID-19 Living Clinical Practice Guidelines

Study ID	Type of Study	Country	Population Description/Setting	Sample Size	Index Test	Index Test Criteria for Positivity	Reader Experience Description	Reference Standard	Number in Reference Section
							emergency physicians		
Vicini 2021	observational, retrospective, single center	Italy	CT images of patients who underwent RT-PCR and chest CT due to COVID-19 suspicion (all symptomatic)	714	CT: not specified	COVID-19 Reporting and Data System (CO-RADS)	2 radiologist with more than 5 years experience; 2 highly experienced radiographers ; 2 less experienced radiographers	RT PCR	[88]
Wang 2020	observational, retrospective, single center	China	suspected of COVID-10 (symptomatic and asymptomatic)	190	CT: not specified	Standardized imaging reporting system: infectious disease, viral pneumonia is highly likely (class 1), infectious lesions, viral pneumonia (class 2), infectious lesions, pathogens to be investigated (class 3), infectious lesions (class 4)	not specified	RT PCR	[89]
Xiong 2020	observational, prospective, single center	China	suspected of COVID-10 (unclear symptomatology)	47	CT: not specified	subpleural GGO without pleural effusion, bronchial changes or lymphadenopathy	radiologist, no details on experience	RT PCR	[90]



## Appendix 4. Detailed Study Appraisal

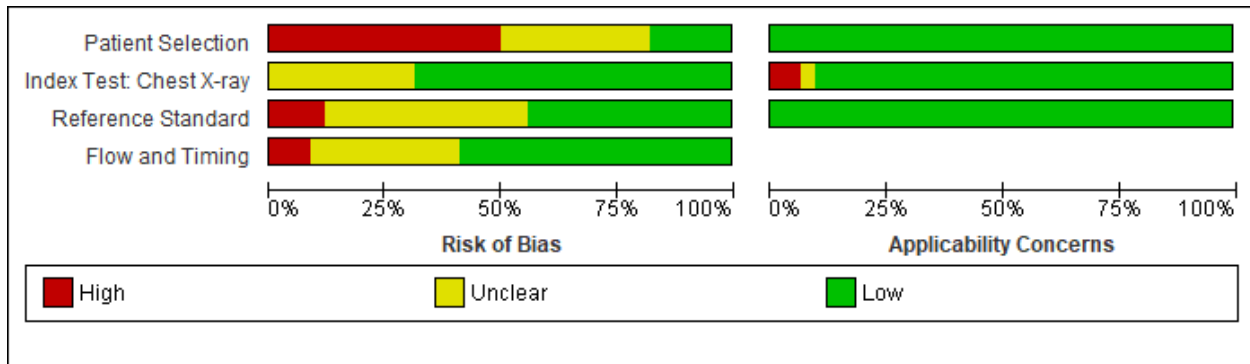


Figure 1. Risk of Bias Ratings of CXR studies

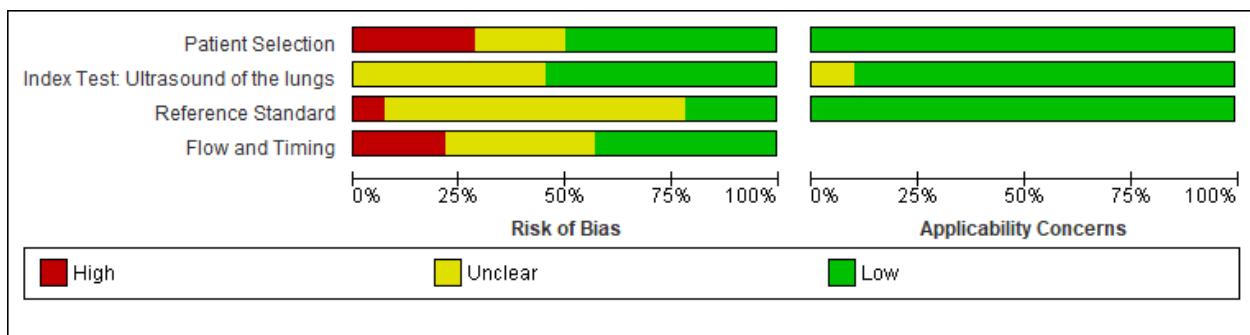


Figure 2. Risk of Bias Ratings of Lung Ultrasound studies

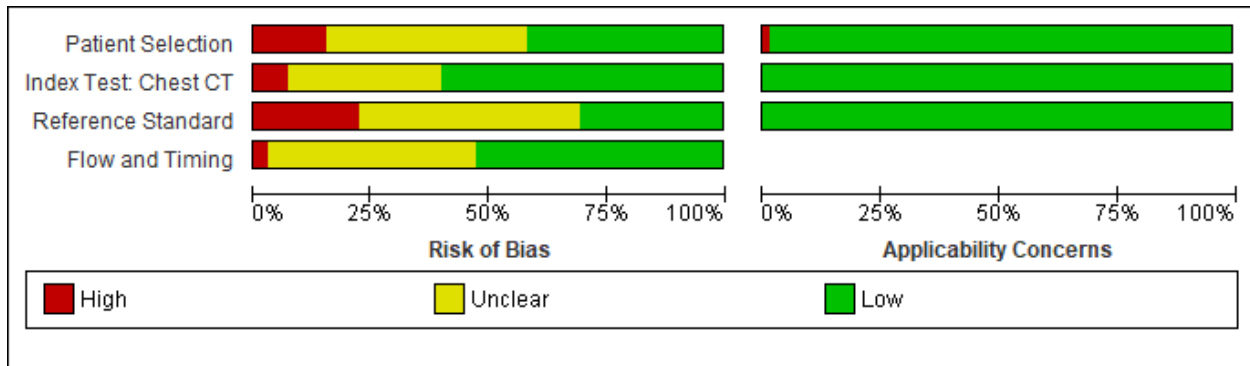


Figure 3. Risk of Bias Ratings of CT scan studies



Appendix 5. Forest Plots

A. Chest X-ray

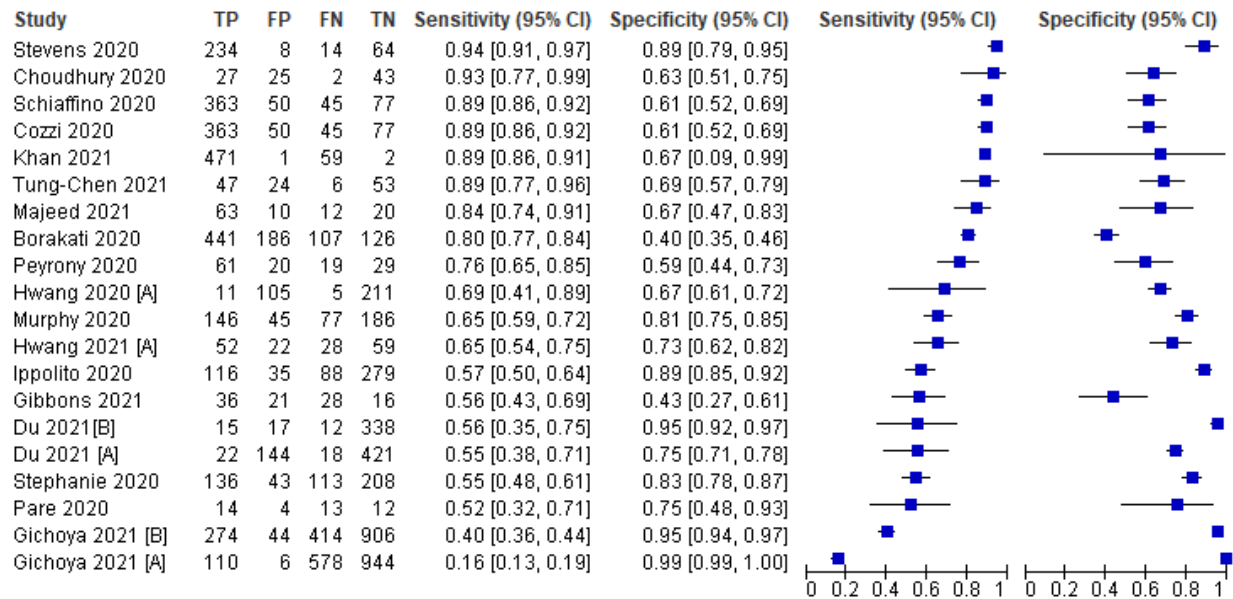


Figure 1. Forest Plot of CXR studies (Overall)

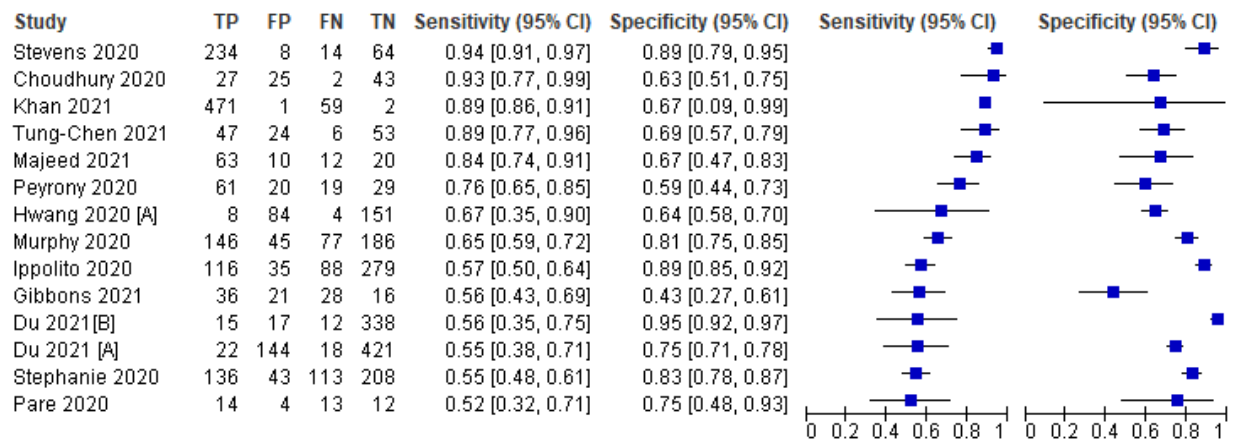


Figure 2. Forest Plot of CXR studies (Subgroup analysis: symptomatic patients)

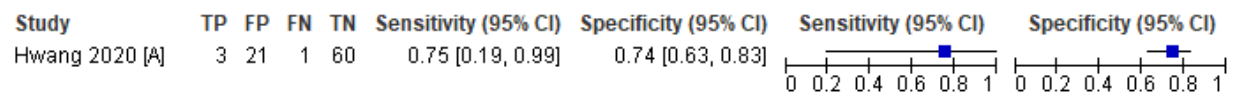


Figure 3. Forest plot of CXR studies (Subgroup analysis: asymptomatic patients)



## Philippine COVID-19 Living Clinical Practice Guidelines

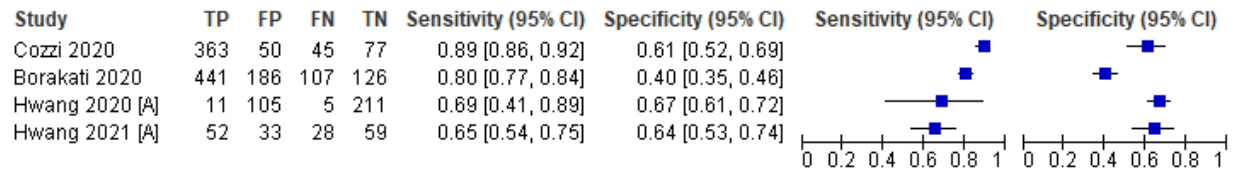


Figure 4. Forest plot of CXR studies (Subgroup analysis: mixed)

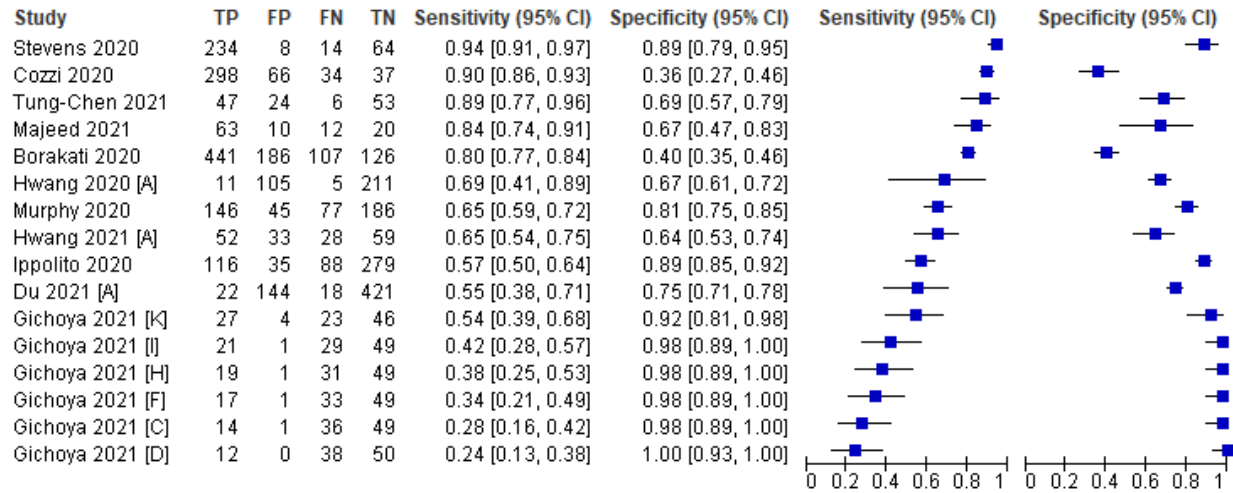


Figure 5. Forest plot of CXR studies (Subgroup analysis: experienced reader)

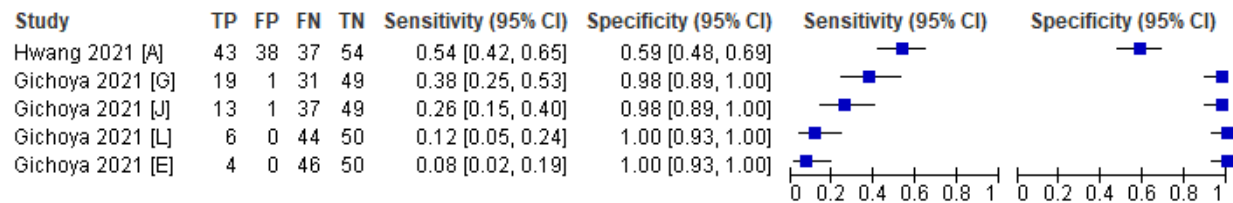


Figure 6. Forest plot of CXR studies (Subgroup analysis: inexperienced reader)

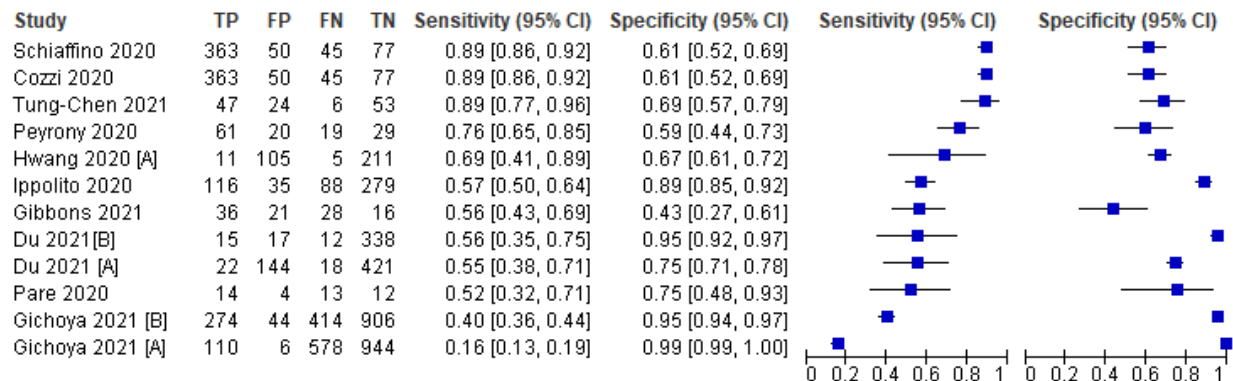


Figure 7. Forest plot of CXR studies (Subgroup analysis: Reader Impression)



# Philippine COVID-19 Living Clinical Practice Guidelines

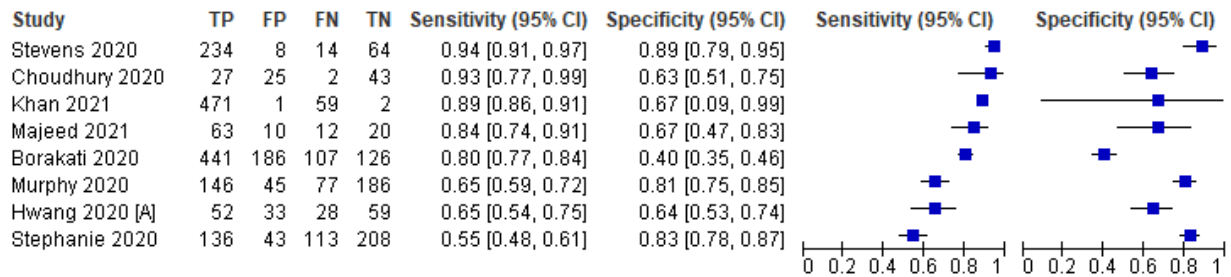


Figure 8. Forest plot of CXR studies (Subgroup analysis: Scoring System)

## B. Lung Ultrasound

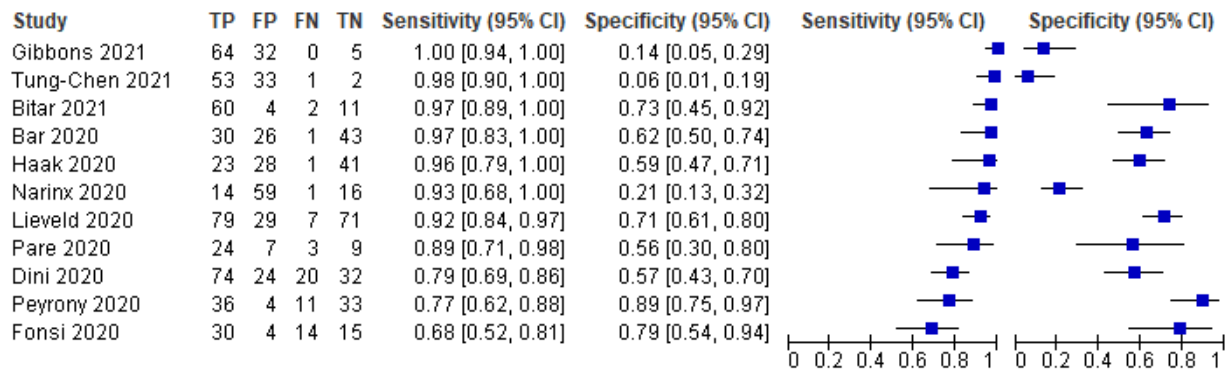


Figure 9. Forest Plot of LUS studies (Overall)

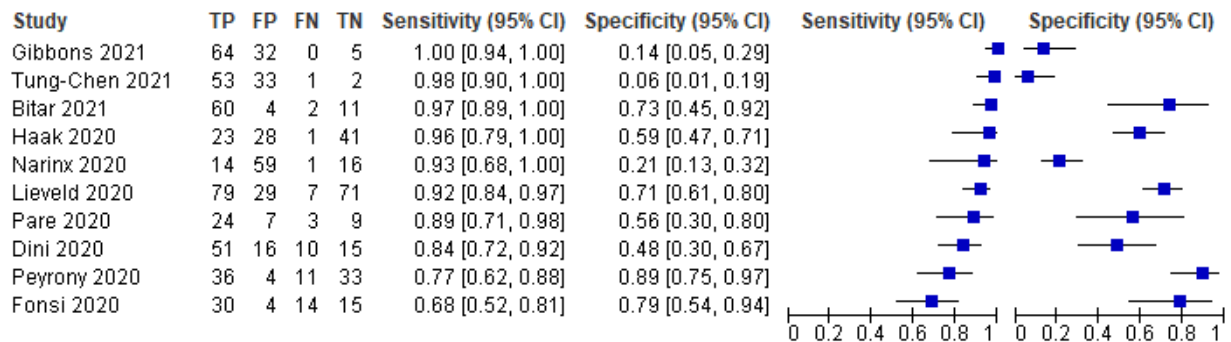


Figure 10. Forest Plot of LUS studies (Subgroup analysis: Symptomatic patients)

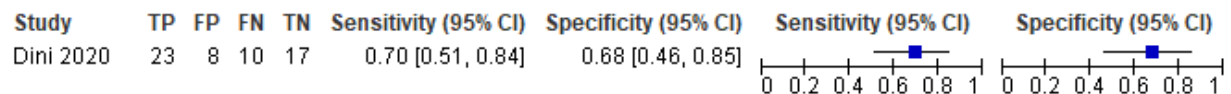


Figure 11. Forest Plot of LUS studies (Subgroup analysis: Asymptomatic patients)

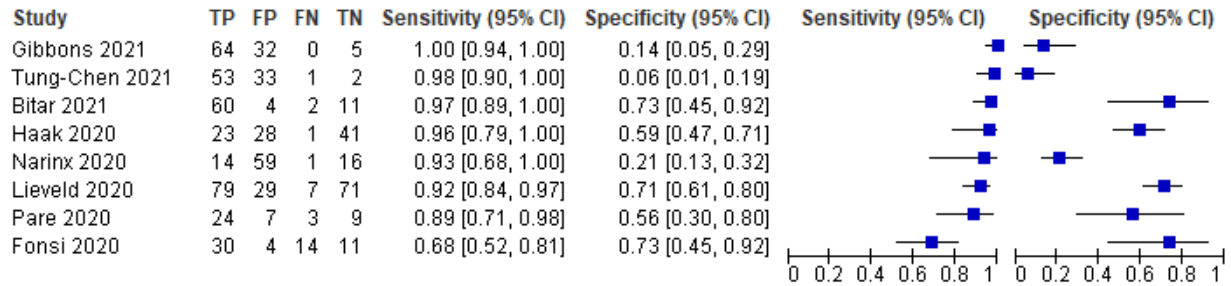


Figure 12. Forest Plot of LUS studies (Subgroup analysis: Experienced reader)

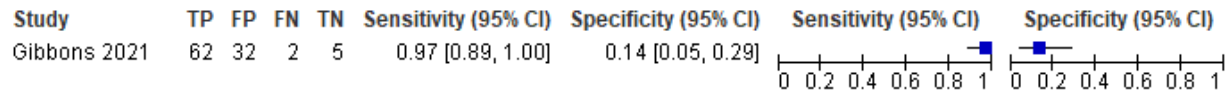


Figure 13. Forest Plot of LUS studies (Subgroup analysis: Inexperienced reader)

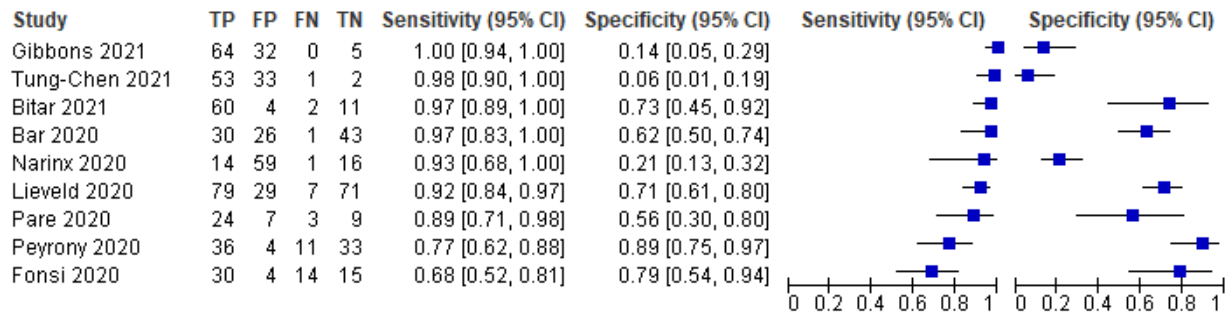


Figure 14. Forest Plot of LUS studies (Subgroup analysis: Reader Impression)

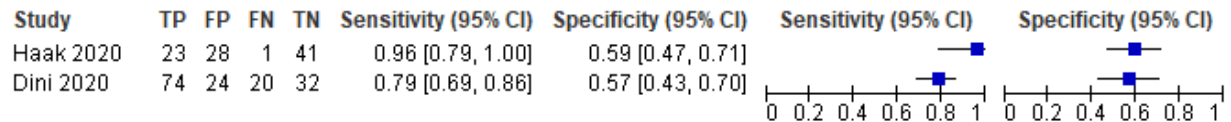


Figure 15. Forest Plot of LUS studies (Subgroup analysis: Scoring System)



## C. Chest CT scan

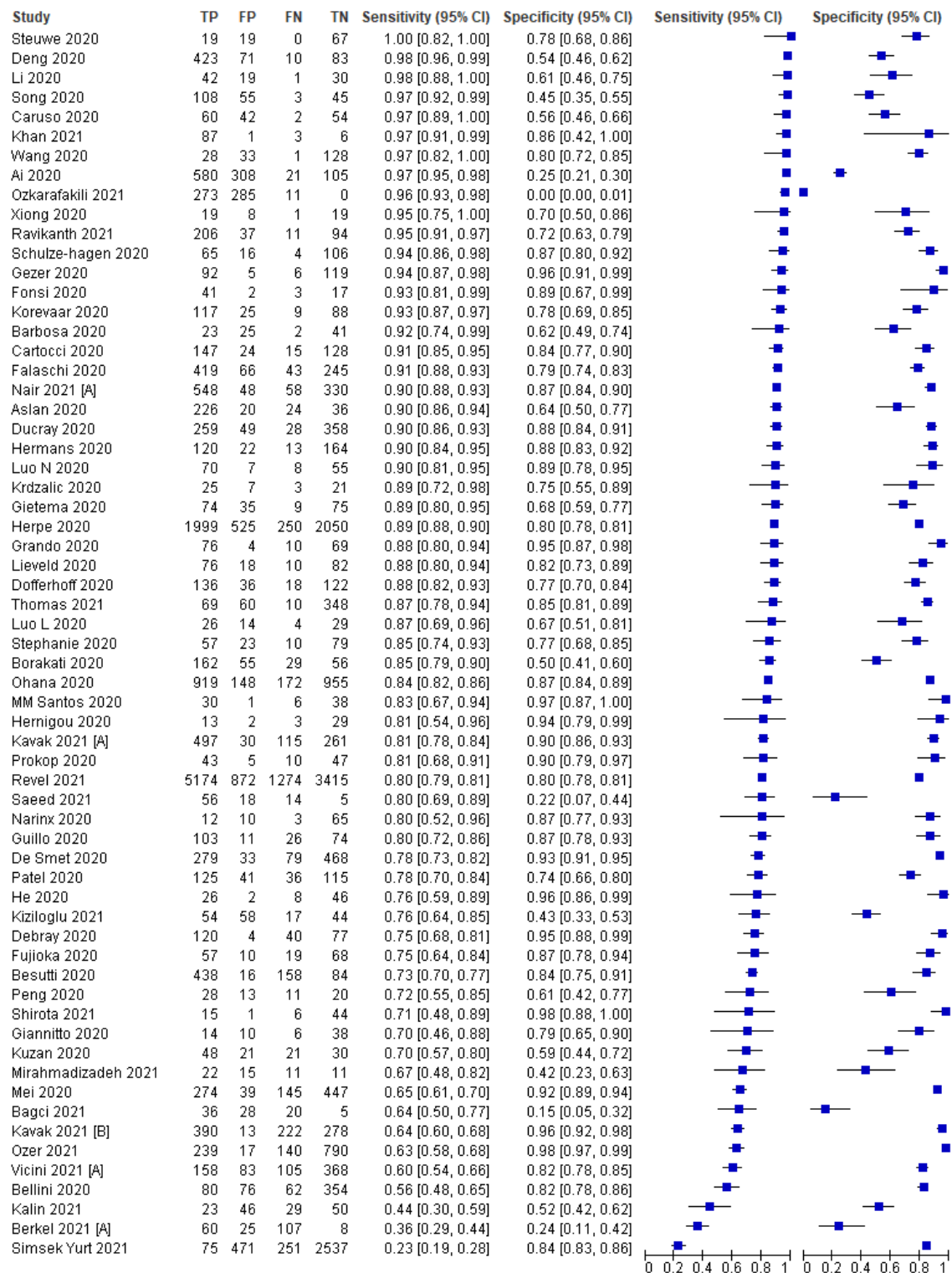


Figure 16. Forest Plot of CT scan studies (Overall)



# Philippine COVID-19 Living Clinical Practice Guidelines

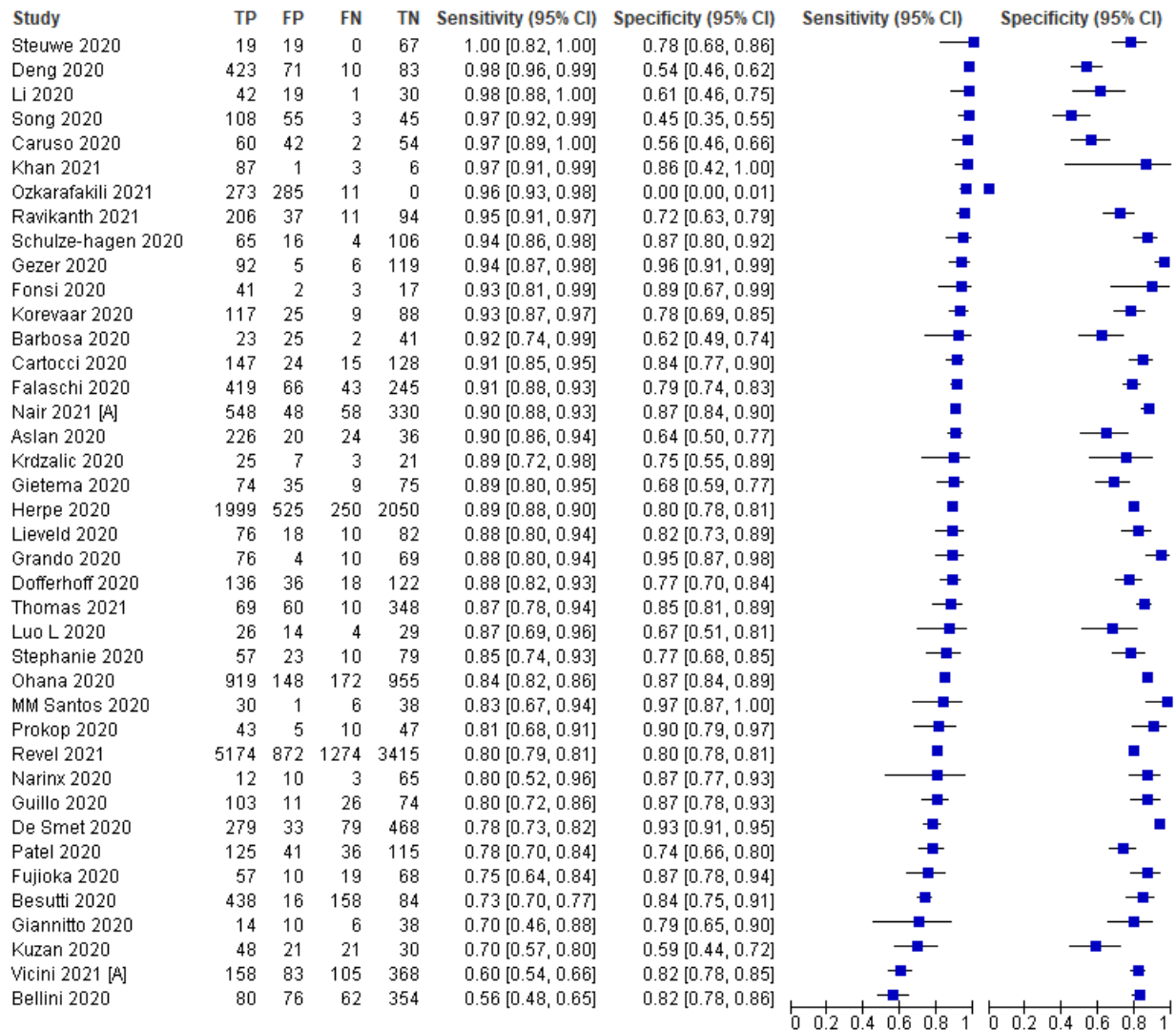
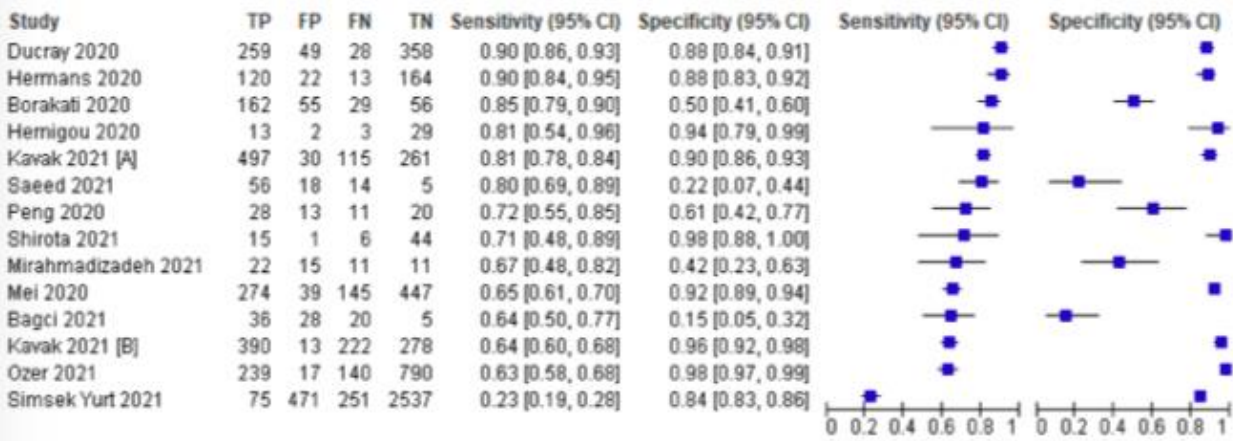


Figure 17. Forest Plot of CT scan studies (Subgroup analysis: symptomatic patients)







# Philippine COVID-19 Living Clinical Practice Guidelines

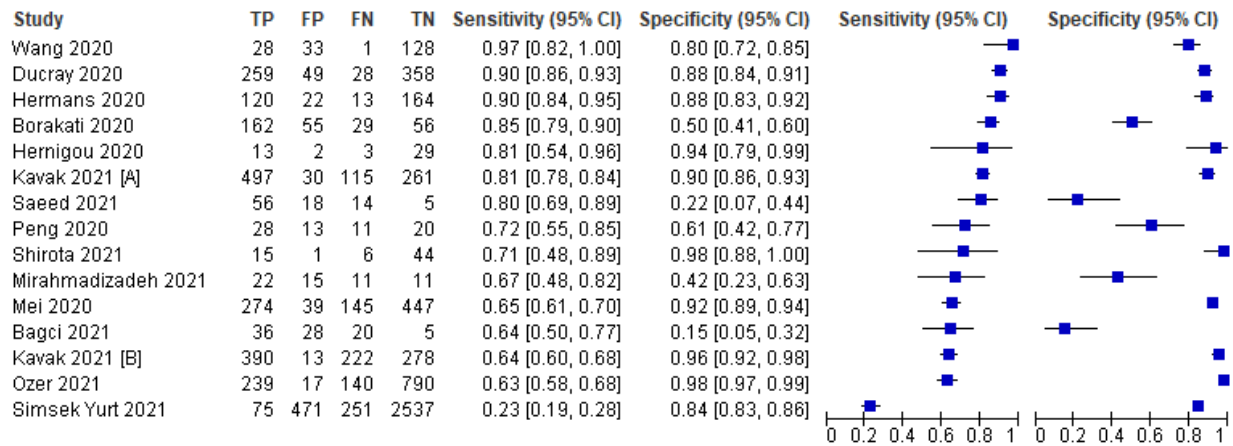
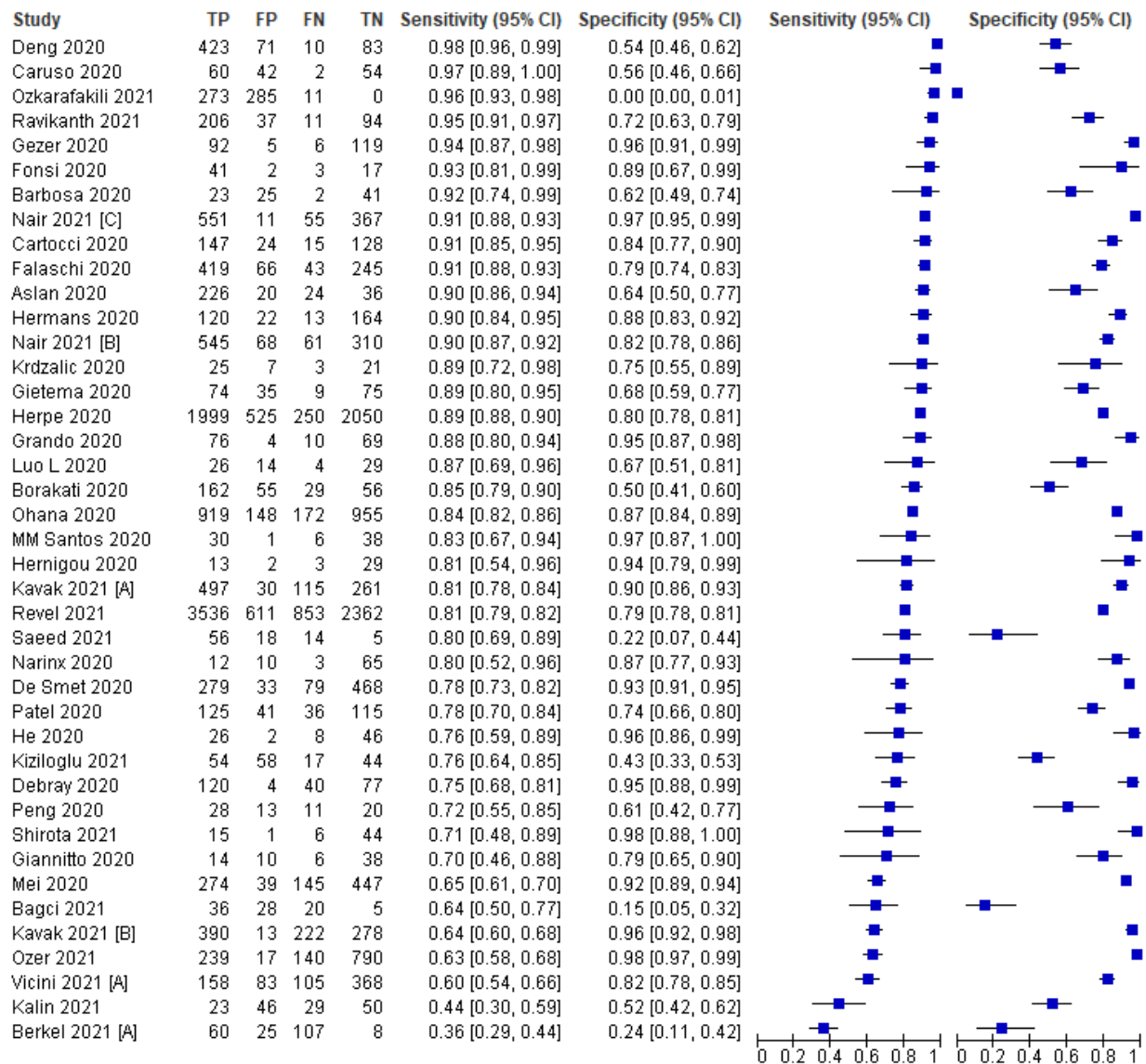


Figure 18. Forest Plot of CT scan studies (Subgroup analysis: both symptomatic& asymptomatic patients)





# Philippine COVID-19 Living Clinical Practice Guidelines

Figure 19. Forest Plot of CT scan studies (Subgroup analysis: experienced readers)

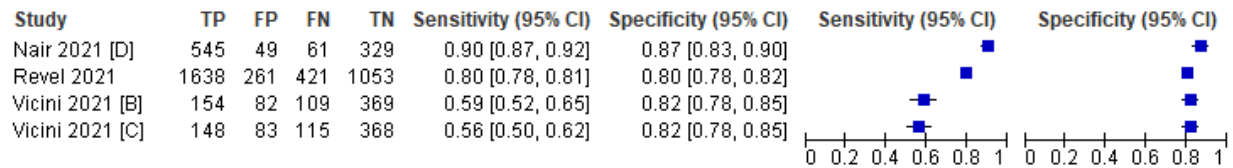


Figure 20. Forest Plot of CT scan studies (Subgroup analysis: inexperienced readers)

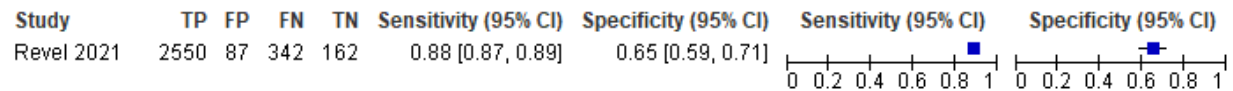


Figure 21. Forest Plot of CT scan studies (Subgroup analysis: Timing of Testing in Relation to Symptom Onset - Late)

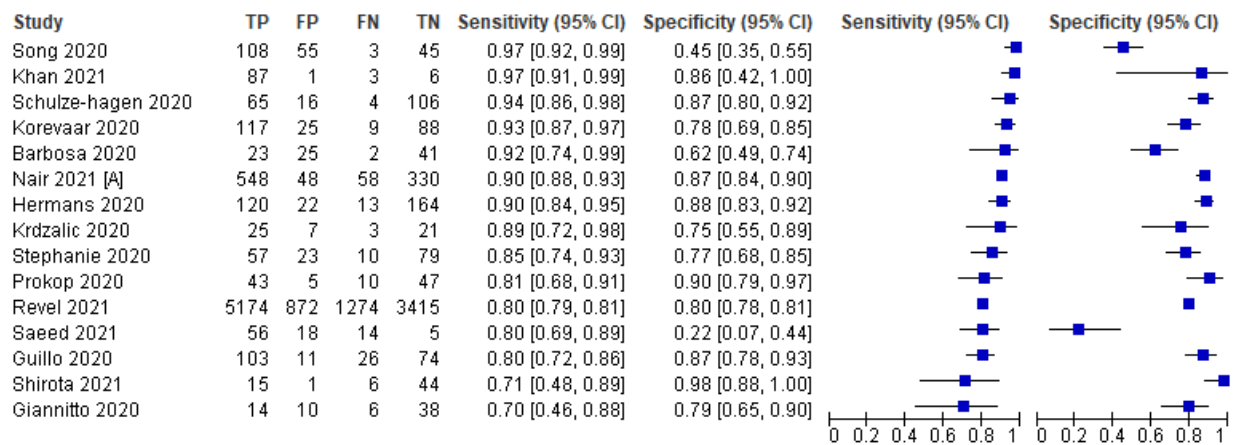


Figure 22. Forest Plot of CT scan studies (Subgroup analysis: Timing of Testing in Relation to Symptom Onset - Mixed: Early & Late)



# Philippine COVID-19 Living Clinical Practice Guidelines

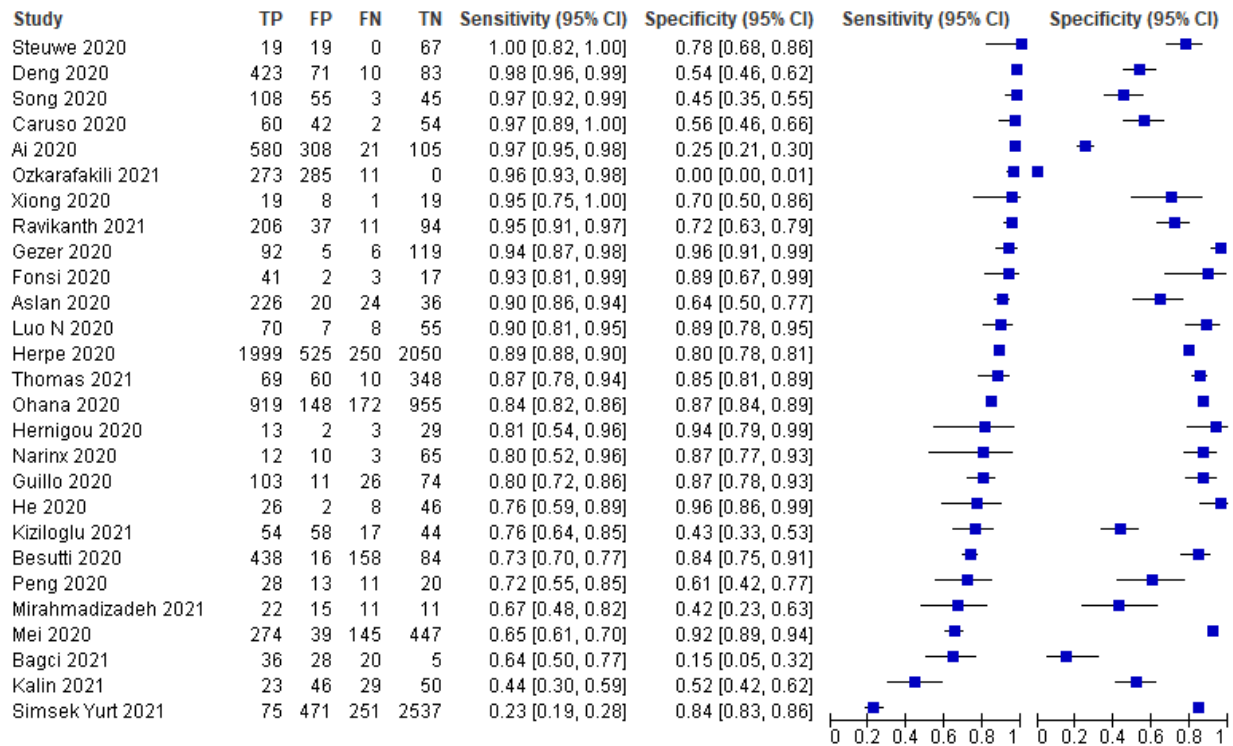


Figure 23. Forest Plot of CT scan studies (Subgroup analysis: Index Test of Positivity - Reader Impression)



# Philippine COVID-19 Living Clinical Practice Guidelines

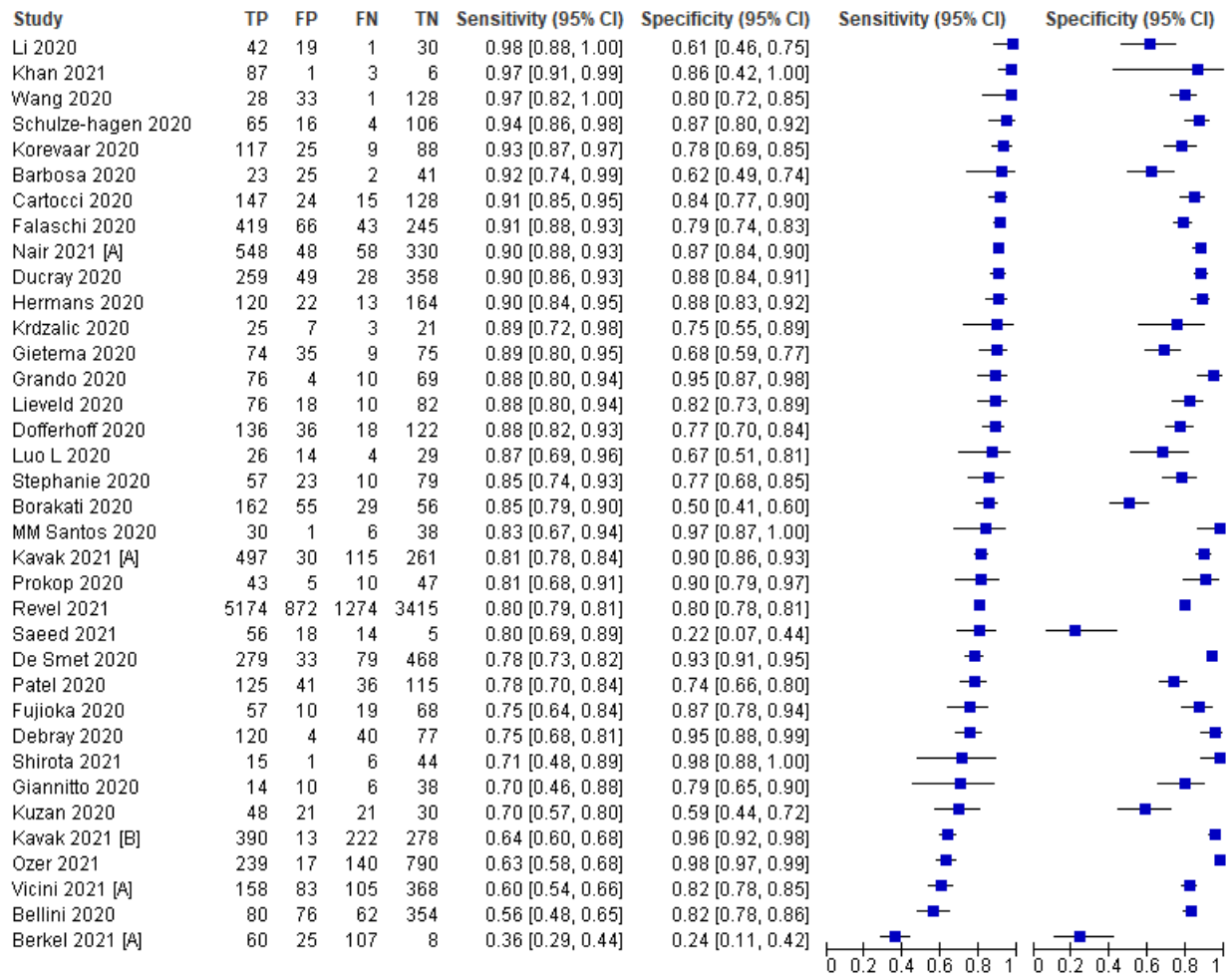
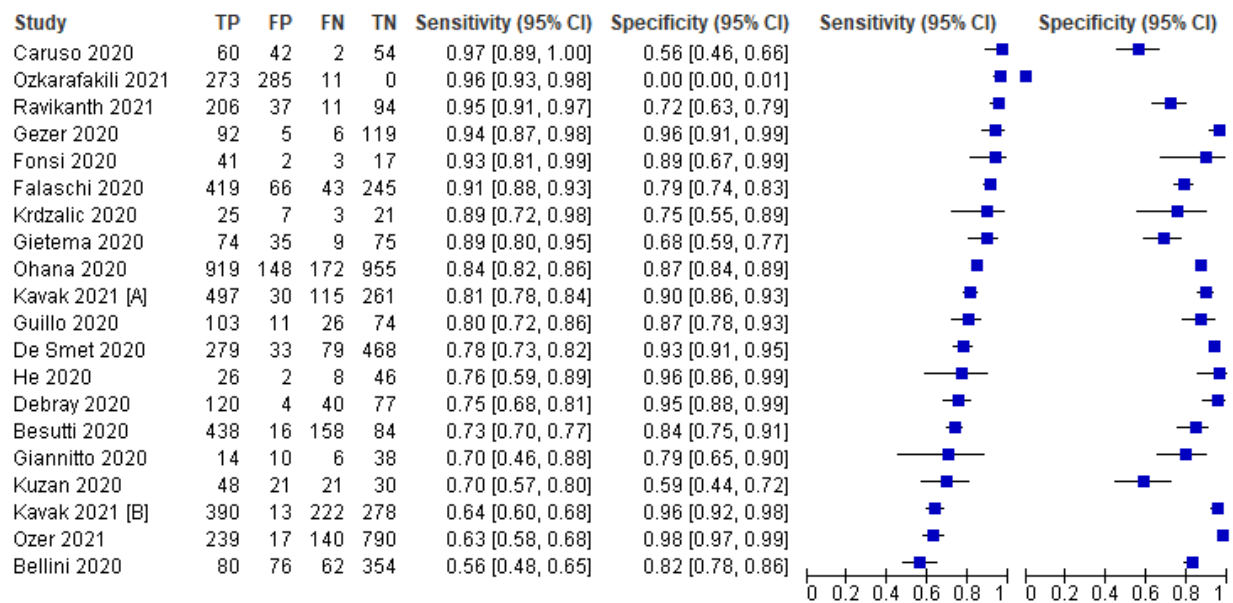


Figure 24. Forest Plot of CT scan studies (Subgroup analysis: Index Test of Positivity -Scoring System)





# Philippine COVID-19 Living Clinical Practice Guidelines

Figure 25. Forest Plot of CT scan studies (Subgroup analysis: Type - Non-contrast enhanced/plain CT scan)

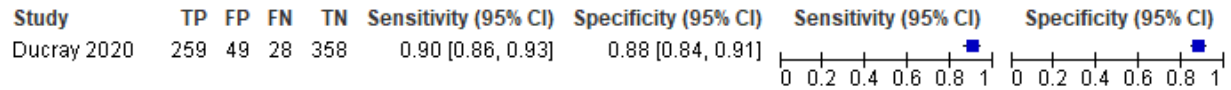


Figure 26. Forest Plot of CT scan studies (Subgroup analysis: Type - Contrast enhanced CT scan)

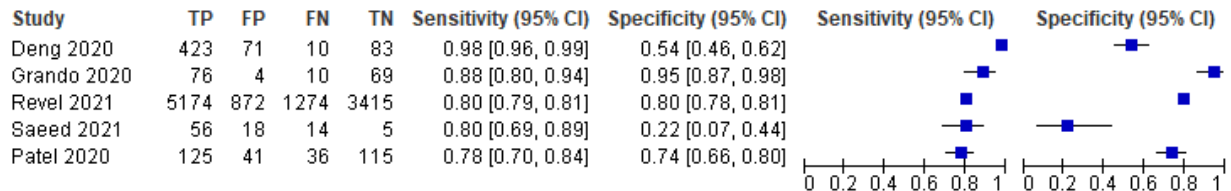


Figure 27. Forest Plot of CT scan studies (Subgroup analysis: Type - High-resolution CT scan)

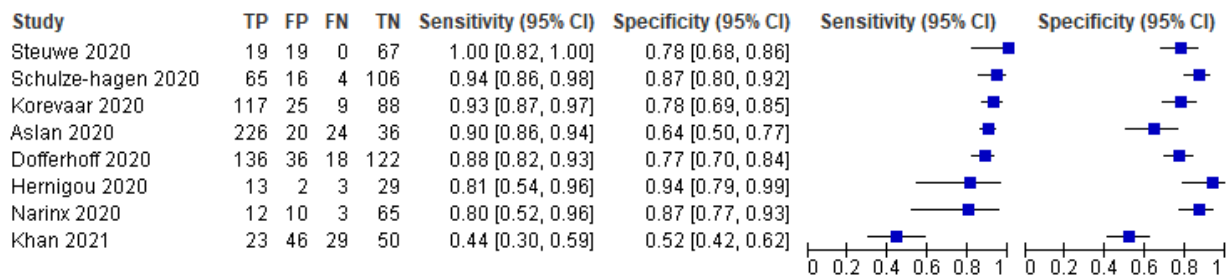


Figure 28. Forest Plot of CT scan studies (Subgroup analysis: Type - Low-dose CT scan)

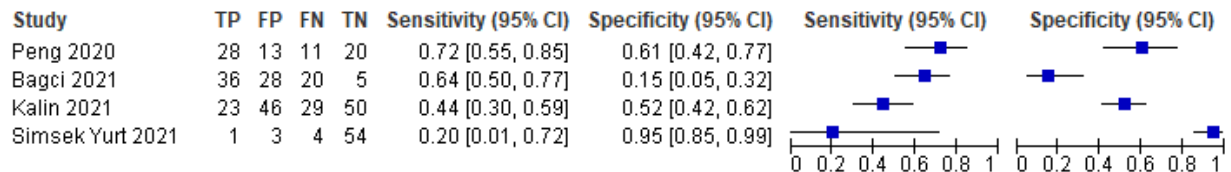


Figure 29. Forest Plot of CT scan studies (Subgroup analysis: Type - Pediatric Population)



# Philippine COVID-19 Living Clinical Practice Guidelines

## Appendix 6. GRADE Evidence

### Should Chest X-ray be used to diagnose COVID-19 in suspected individuals?

Pooled sensitivity: 0.72 (95% CI: 0.61 to 0.81)

Pooled specificity: 0.78 (95% CI: 0.67 to 0.86)

Outcomes	No of studies (patient)	Study design	Factors that may decrease certainty of evidence					Effect per 1,000 patients tested			Test Accuracy CoE
			Risk of bias	Indirectness	Inconsistency	Imprecision	Publication Bias	Pre-test probability of 5%	Pre-test probability of 10%	Pre-test probability of 20%	
<b>True positives</b> (patients with COVID-19)	18 studies (9,616 patients)	cohort & case-control type studies	very serious <sup>a</sup>	not serious	very serious <sup>b</sup>	serious <sup>c</sup>	none	36 (31 to 41)	72 (61 to 81)	108 (92 to 122)	⊕○○○ Very Low
<b>False negatives</b> (patients incorrectly classified as not having COVID-19)								14 (9 to 19)	28 (19 to 39)	42 (28 to 58)	
<b>True negatives</b> (patients without COVID-19)	18 studies (9,616 patients)	cohort & case-control type studies	very serious <sup>a</sup>	not serious	very serious <sup>b</sup>	very serious <sup>d</sup>	none	741 (637 to 817)	702 (603 to 774)	663 (570 to 731)	⊕○○○ Very Low
<b>False positives</b> (patients incorrectly classified as having COVID-19)								209 (133 to 313)	198 (126 to 297)	187 (119 to 280)	

CI: confidence interval

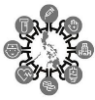#### Explanations

a. high risk on patient selection, conduct of reference standard, and patient flow and timing plus unclear risk on all four domains

b. considerable heterogeneity ( $I^2 = 95\%$ )

c. wide confidence intervals

d. very wide values in confidence interval



# Philippine COVID-19 Living Clinical Practice Guidelines

## Should lung ultrasound be used to diagnose COVID-19 in suspected individuals?

**Pooled sensitivity:** 0.93 (95% CI: 0.86 to 0.97)

**Pooled specificity:** 0.52 (95% CI: 0.33 to 0.71)

Outcomes	No of studies (patient)	Study design	Factors that may decrease certainty of evidence					Effect per 1,000 patients tested			Test Accuracy CoE
			Risk of bias	Indirectness	Inconsistency	Imprecision	Publication Bias	Pre-test probability of 5%	Pre-test probability of 10%	Pre-test probability of 20%	
<b>True positives</b> (patients with COVID-19)	11 studies (1,076 patients)	cross-sectional (cohort type accuracy study)	serious <sup>a</sup>	not serious	very serious <sup>b</sup>	serious <sup>c</sup>	none	47 (43 to 49)	93 (86 to 97)	140 (129 to 146)	⊕○○○ Very Low
<b>False negatives</b> (patients incorrectly classified as not having COVID-19)								3 (1 to 7)	7 (3 to 14)	10 (4 to 21)	
<b>True negatives</b> (patients without COVID-19)	11 studies (1,076 patients)	cross-sectional (cohort type accuracy study)	serious <sup>a</sup>	not serious	very serious <sup>b</sup>	very serious <sup>d</sup>	none	494 (314 to 675)	468 (297 to 639)	442 (281 to 603)	⊕○○○ Very Low
<b>False positives</b> (patients incorrectly classified as having COVID-19)								456 (275 to 636)	432 (261 to 603)	408 (247 to 569)	

**CI:** confidence interval

### Explanations

- a. mostly unclear risk on all four domains
- b. considerable heterogeneity (I<sup>2</sup> = 98%)
- c. wide confidence intervals
- d. very wide values in the confidence intervals



# Philippine COVID-19 Living Clinical Practice Guidelines

## Should chest CT scan be used to diagnose COVID-19 in suspected individuals?

**Pooled sensitivity:** 0.85 (95% CI: 0.81 to 0.87)

**Pooled specificity:** 0.78 (95% CI: 0.71 to 0.83)

Outcomes	No of studies (patient)	Study design	Factors that may decrease certainty of evidence					Effect per 1,000 patients tested			Test Accuracy CoE
			Risk of bias	Indirectness	Inconsistency	Imprecision	Publication Bias	Pre-test probability of 5%	Pre-test probability of 10%	Pre-test probability of 20%	
<b>True positives</b> (patients with COVID-19)	62 studies (39,929 patients)	cohort & case-control type studies	serious <sup>a</sup>	not serious	very serious <sup>b</sup>	serious <sup>c</sup>	none	43 (41 to 44)	85 (81 to 87)	128 (122 to 131)	⊕○○○ Very Low
<b>False negatives</b> (patients incorrectly classified as not having COVID-19)								7 (6 to 9)	15 (13 to 19)	22 (19 to 28)	
<b>True negatives</b> (patients without COVID-19)	62 studies (39,929 patients)	cohort & case-control type studies	serious <sup>a</sup>	not serious	very serious <sup>b</sup>	very serious <sup>d</sup>	none	741 (675 to 789)	702 (639 to 747)	663 (603 to 705)	⊕○○○ Very Low
<b>False positives</b> (patients incorrectly classified as having COVID-19)								209 (161 to 275)	198 (153 to 261)	187 (145 to 247)	

**CI:** confidence interval

### Explanations

- a. mostly unclear risk on all four domains
- b. considerable heterogeneity (I<sup>2</sup>=100%)
- c. wide confidence intervals
- d. very wide values in confidence intervals





## Philippine COVID-19 Living Clinical Practice Guidelines

### Appendix 7. Characteristics of Ongoing Studies

NCT Number	Title	Population	Interventions	Comparator	Outcomes
NCT04479319 [97]	Decision Support System Algorithm for COVID-19 Diagnosis	Adult patients with a differential diagnosis of COVID-19 and tested for it with Thorax CT and RT-PCR in Turkey.	Thorax CT	RT-PCR for SARS-CoV-2.	Diagnosing COVID-19 (Determination of sensitivity and specificity in predicting COVID-19 diagnosis of hybrid decision support system)
NCT04377685 [98]	Prediction of Clinical Course in COVID19 Patients (COVID-CTPRED)	patient admitted to the emergency room of COVID-19 confirmed by RT-PCR	Chest CT scan on admission to the hospital	RT-PCR for SARS-CoV-2.	diagnostic of COVID disease composite
NCT04339686 [99]	Multicentric Retrospective Observational Study of Thoracic Scanner Performance in COVID Screening.	All patients suspected of COVID 19 consulting for diagnostic	Thoracic CT Scan	RT-PCR for SARS-CoV-2.	Diagnostic performance of chest CT in screening for pulmonary lesions in clinical suspicions of COVID; Compare the diagnostic performance of chest CT and RT-PCR in COVID 19 at the initial consultation (screening)
NCT04357938 [100]	Risk Stratification With Chest CT to Rule-out Suspected SARS-CoV-2 Infections (SCout)	Patients with unspecific symptoms of SARS-CoV-2 infection who are to be admitted to hospital for any disease and who provide written informed consent to undergo rt-PCR, chest CT, and antibody test.	Chest CT imaging	RT-PCR for SARS-CoV-2.	Sensitivity and specificity of chest CT in detecting pneumonia in unspecific symptomatic patients who are to be admitted to hospital and who are rt-PCR negative for SARS-CoV-2;
NCT04370275 [101]	Accuracy of Lung Ultrasound in the Diagnosis of covid19 Pneumonia: a Multicenter Study in the Italian Outbreak	People entering the Emergency Room during the SARS-CoV-2 epidemic	Lung Ultrasound	RT-PCR	Negative Predictive Value, Positive Predictive Value, Sensitivity and Specificity Lung Ultrasound in the diagnosis of COVID-19
NCT04353141 [102]	International Lung UltraSound Analysis (ILUSA) Study (ILUSA)	All consecutive pregnant patients who are admitted to the hospital for delivery, cesarean section or admission for at least one night.	standardized Lung Ultrasound (LUS) examination	RT-PCR	Diagnostic performance of LUS to predict poor outcome
NCT04327674 [103]	The Use of Focused Lung Ultrasound in Patients Suspected of COVID-19	All patients who have symptoms on COVID-19 and is seen at a hospital.	Focuses Lung Ultrasound	RT-PCR & chest x-ray	FLUS findings and respiratory failure; FLUS findings and SAR-CoV-2 PCR-test result; FLUS findings and admission to intensive care; FLUS findings and chest x-ray



## Philippine COVID-19 Living Clinical Practice Guidelines

NCT Number	Title	Population	Interventions	Comparator	Outcomes
NCT04561024 [104]	Evaluation of a COVID-19 Pneumonia CXR AI Detection Algorithm	There will be three subsets of study population in this study; patients who were: (1) RT-PCR confirmed COVID-19 positive; (2) RT-PCR confirmed COVID-19 negative; (3) either had a diagnosis of pneumonia before the 1st January 2020.	Deep Learning CNN model in chest x-ray	RT-PCR	Diagnostic Performance of AI model